

Relative Recirculation Abnormalities in Collapsed Lung: A Metric For Vascular Tortuosity?

C. K. Macgowan^{1,2}, S. Wu², R. Tessler³, J. Belik^{2,4}, and A. Kassner^{2,5}

¹Medical Biophysics, University of Toronto, Toronto, ON, Canada, ²Physiology and Experimental Medicine, Hospital for Sick Children, Toronto, ON, Canada, ³Pediatrics, Pontificia Universidade Catolica do Rio Grande do Sul, Rio Grande do Sul, Brazil, ⁴Pediatrics, University of Toronto, Toronto, ON, Canada, ⁵Medical Imaging, University of Toronto, Toronto, ON, Canada

Introduction

Respiratory distress syndrome (RDS) affects approximately 1% of newborn children and is the leading cause of death in pre-term infants. It is characterized by regional lung collapse (atelectasis) resulting from low surfactant production in the immature lung. Atelectasis results in shortening and folding of the alveolar walls, leading to abnormal and tortuous microvasculature [1]. Relative recirculation (rR) obtained from dynamic perfusion MRI has been proposed previously as a metric of microvessel tortuosity [2]. The goal of this study was to investigate this metric in a porcine model of acute lobar atelectasis (regional lung collapse). It was hypothesized that rR would increase in regions of collapse.

Materials & Methods

Yorkshire piglets (N=4) were studied under sedation. Acute unilateral lobar atelectasis was achieved as described previously [3]. Animals were ventilated with pure oxygen prior to occluding/collapsing the right lower lobe. Imaging was performed on a 1.5 T MR system (GE Healthcare, USA) using an 8-channel knee coil. Before and after collapse, DCE MR data were acquired using a 3D gradient echo TRICKS sequence [4]. Imaging parameters were as follows: TR/TE = 2.6/1.0 ms, flip angle = 45°, FOV= 200×140×288 mm, fractional k space = 75%, matrix = 128×96×32, temporal resolution ≈ 1 s, scan time ≈ 56 s. Gd-DTPA (Magnevist, Berlex, Canada) was administered with a power injector (Medrad, USA) shortly after the start of each 3D scan. Scans were separated by approximately 30 minutes to allow for uniform redistribution of the first dose. Regions of interest were drawn in the parenchyma of the right and left lower lobes, before and after collapse. The average signal within each ROI was calculated as a function of time and baseline corrected by subtracting the mean pre-contrast signal. A gamma-variate fit was then performed for each curve using data between the onset of contrast enhancement and the half-peak height of the wash-out phase. rR values were then calculated using the equation from Fig. 1. Mean rR differences before and after collapse were then tested using a paired Students t-test for both left and right lobes. Differences between left and right mean rR, prior to collapse, were tested using an F-test. Significance was defined as p < 0.05.

Results

Mean rR values before collapse were significantly different from mean rR values after collapse in the right lobe (0.19±0.08 vs 0.36±0.10, p<0.05) but not in the left. No significant differences of rR values were found between left and right lobes before collapse. A summary of the results is presented in Figure 2.

Conclusion

Our findings show increased rR values in the collapsed lung which we believe is associated with architectural remodeling. This study will improve our understanding of this physiological process, and rR may provide a new metric for studying diseases of the lung including emphysema or acute pulmonary distress syndrome.

References

- [1] Loosli *et al.* Anat. Rec. 105:697-721 (1949) [2] Kassner *et al.* JMRI 11:103-113 (2000) [3] Tessler *et al.* Pediatr. Res. 64:251-255 (2008) [4] Korosec *et al.* MRM 36:345-351 (1996)

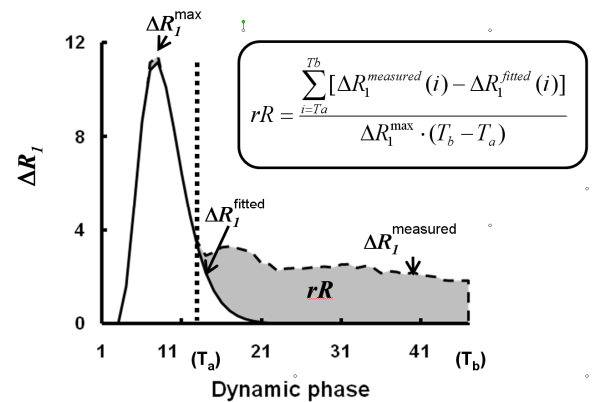


Figure 1: Definition of relative recirculation (rR).

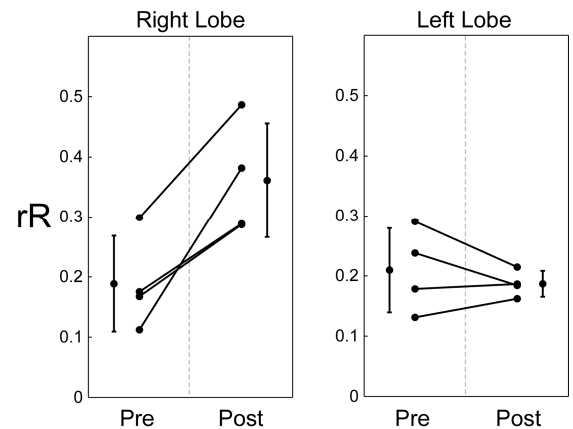


Figure 2: rR from right and left lobes, before (Pre) and after (Post) collapse.