

Changes in breast tumor K_{ps} and ADC after treatment with the VEGFR-TK inhibitor AG-013736 correlate with changes in tumor volume

L. J. Wilmes¹, K-L. Li², L. M. Fleming², M. G. Pallavicini³, S. C. Partridge⁴, S. Aliu², and N. M. Hylton²

¹University of California San Francisco, San Francisco, CA, United States, ²University of California San Francisco, ³University of California Merced, ⁴University of Washington

Background: New therapies designed to block the formation of blood vessels necessary for tumor survival and metastases are showing promise for improving the efficacy and selectivity of cancer treatment. AG-013736, a novel and potent inhibitor of the vascular endothelial growth factor receptor (VEGFR) tyrosine kinases (TKs) has shown anti-tumor activity in xenograft models of cancer [1] and in phase I clinical trials [2, 3]. The ability to non-invasively assess the anti-tumor effects of targeted agents can aid in the development and assessment of new therapeutics. Utilizing dynamic contrast enhanced (DCE) MRI is a logical choice for studying VEGFR-TKIs because this technique can provide quantitative measures of tumor microvasculature such as endothelial transfer coefficient (K^{ps}) and fractional plasma volume (fPV). Alternatively, diffusion-weighted (DW)-MRI is sensitive to different cellular properties such as cellular density and microstructure. Previous work has shown that the apparent diffusion coefficient of water (ADC) measured by DW-MRI can be a sensitive indicator of response to treatments such as chemotherapy and radiation [4]. The goal of this work was to evaluate how well AG-013736 –induced changes in DCE-MRI and DW-MRI correlate with tumor volume, a clinically relevant measure of treatment response.

Methods: Female nude mice were implanted with the human breast cancer line BT474, a Her2/neu overexpressing variant. Treated mice (n=4) received 25 mg/kg i.p. b.i.d., of AG-013736 while control mice (n=4) received an equivalent volume of vehicle for 7 days. Tumor-bearing mice were imaged in pairs prior to and after 7 days of treatment. During imaging, mice were anesthetized with 1.5% isoflurane. Imaging was performed on a 1.5T GE Signa scanner (General Electric Medical Systems, Milwaukee, WI) using a conventional wrist coil and customized animal holder. Pre-contrast tumor T1 was measured using a 3D variable flip angle fast gradient echo technique. For DCE-MRI studies, mice were injected i.v. with 0.03 mmol/kg Albumin GdDTPA₃₀. Contrast-enhanced imaging was performed using a coronal T1-weighted 3D gradient echo sequence (TR/TE10.4/4.2 ms, FOV 10 cm, matrix 256 x 192, slice thickness 1.0 mm, 1 NEX). A two-compartment model [5] incorporating the individual arterial input function (AIF) for each mouse was utilized to calculate the endothelial transfer constant (K^{ps}) and fractional plasma volume (fPV) for each tumor. Diffusion weighted images were acquired from the same mice using a single shot fast spin echo sequence (TR/TE=27/8ms, FOV=10 cm, b=0,600 s/m²). Tumor regions of interest were drawn on 3D images to determine tumor volumes and also for delineation of tumors on ADC maps.

Results: The change in mean tumor K^{ps}, ADC and volumes after 7 days of treatment are shown in Figure 1a, b, and c respectively. A significant decrease in K^{ps} (-91%, p<0.05) was found after treatment with AG-013736 with a smaller decrease in K^{ps} (-33%) seen in the control tumors. Minimal decreases in tumor fPV were found for both groups. The treated tumors also showed an increase in mean tumor ADC (27%) after 7 days of treatment, while the control group showed a decrease in ADC (-27%). There was clear tumor growth inhibition in the treated group and continued growth in the control group. When the tumor MRI data were entered into a stepwise multivariate analysis to identify independent MR measures that were significantly correlated with 7 day change in tumor volume, only absolute change in tumor K^{ps} and ADC were found to be significant (p<0.05).

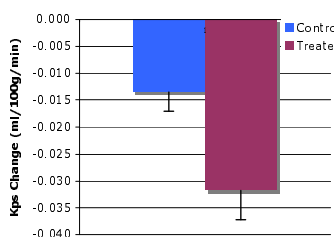


Figure 1a. Tumor K_{ps} changes

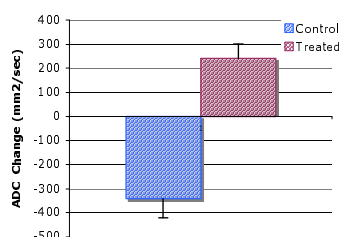


Figure 1b. Tumor ADC changes

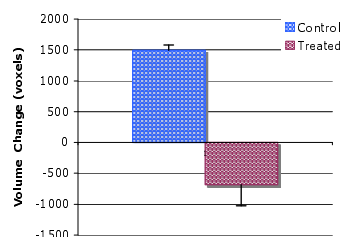


Figure 1c. Tumor volume changes

Discussion: These preliminary results demonstrated that treatment with AG-013736 resulted in large changes in both mean tumor K^{ps} and ADC that were different than those observed for the control group. When MRI-measured tumor variables from both groups were evaluated, significant independent correlations between tumor volume change and changes in both tumor K^{ps} and tumor ADC were found. These results suggest that change in K^{ps} in combination with change in ADC may provide a more sensitive measure of tumor response to anti-angiogenic agents such as VEGFR receptor tyrosine kinase inhibitors and may reflect different aspects of treatment response.

References: [1] Hu-Lowe D et al., Clin Canc Res, Nov 2008. [2] Rugo HS et al., J Clin Oncol, 2005; 23(24):5474-83. [3] Wilmes LJ et al., Mag Reson Image, 2007; 25(3):319-27. [4] Jennings D, Neoplasia, 2002; 4(3):255-62. [5] Patlak CS et al., J Cereb Blood Flow Met, 1983; 3:7.

Acknowledgements: NIH Grant 2ROICA69587 and the UCSF Cancer Center Animal Core.