

Quantification of hepatic perfusion fraction using diffusion-weighted imaging with multiple b-values: utility for the diagnosis of liver cirrhosis

J. Patel¹, E. Sigmund¹, J. Jensen¹, H. Rusinek¹, M. Oei¹, and B. Taouli¹

¹NYU Medical Center, New York, NY, United States

Introduction: There is data suggesting that hepatic apparent diffusion coefficient (ADC) is decreased in patients with liver fibrosis and cirrhosis, however with some degree of overlap between normal and cirrhotic liver [1]. It has been shown in other models that DWI provides simultaneous diffusion and microcirculation information provided these two parameters can be separated [2]. Since liver perfusion is affected in advanced liver fibrosis and cirrhosis [3], the objective of our study was to develop a non contrast method based on SS EPI DWI for the estimation of advanced diffusion parameters, including ADC and perfusion fraction (PF), for the diagnosis of cirrhosis.

Methods: DWI was prospectively obtained on 7 cirrhotic patients and 7 patients with normal liver at 1.5T. All subjects underwent free breathing or respiratory triggered SS EPI DWI (using 9 b-values, 0, 50, 100, 150, 200, 300, 500, 700 and 1000 s/mm²). Post processing analysis of DWI included: ADC^{Total} (using all b-values), true diffusion coefficient (ADC^{High}) (using b > 200) and PF (in %). PF was calculated as $PF = (SI_0 - SI_{int}) / SI_0$ where SI_0 is the measured SI (signal intensity) for b₀, and SI_{int} is the y intercept point of a linear curve fit equation generated from ADC^{High}. Each diffusion-weighted dataset was derived from a large ROI in the right hepatic lobe. Spatially resolved maps of the diffusion parameters were also generated and compared qualitatively with ROI results.

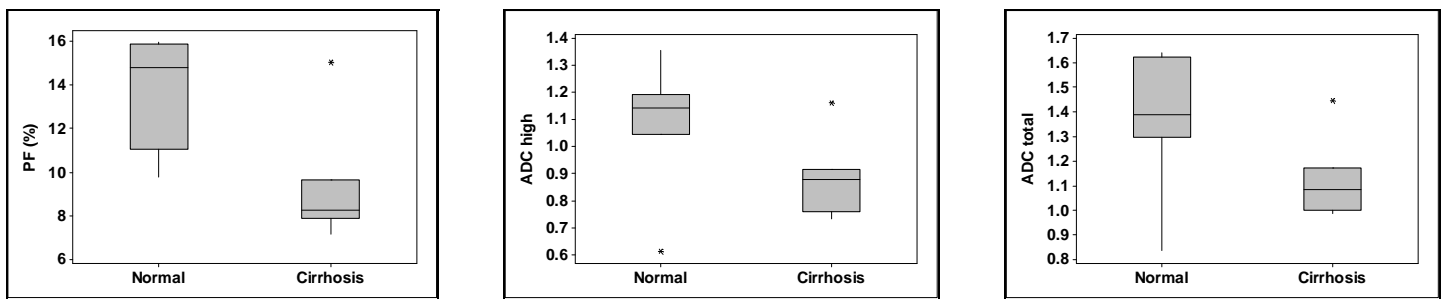


Figure 1: Box plots of diffusion parameters (PF-left, ADC^{High}-middle, and ADC^{Total}-right) in normal and cirrhotic livers (top and bottom of the boxes represent 25-75% percentiles, line in the box represents the median value)

Results: Liver ADC^{Total} and ADC^{High} ($\times 10^{-3}$ mm²/sec) were lower in cirrhosis (1.12 ± 0.16 and 0.88 ± 0.14) compared to normal liver (1.36 ± 0.27 and 1.09 ± 0.14) without reaching significance ($p=0.09$). Liver PF (in %) was significantly lower in cirrhosis compared to normal liver (9.28 ± 2.66 vs. 13.47 ± 2.56 , $p=0.01$), with almost no overlap between normal and cirrhotic livers (**Fig. 1**). **Fig. 2** shows example parametric maps for the diffusion metrics for a normal subject and cirrhotic patient. Quantitative values in each case are consistent with large ROI group analysis. Sensitivity, specificity, PPV and NPV for the diagnosis of cirrhosis are listed in **Table 1**.

| | PF (< 9.7%) | ADC ^{Total} (<1.2) | ADC ^{High} (<1.0) |
|--------------|----------------|--------------------------------|-------------------------------|
| Sens. | 0.857 | 0.857 | 0.857 |
| Spec. | 1.0 | 0.857 | 0.857 |
| PPV | 1.0 | 0.857 | 0.857 |
| NPV | 0.875 | 0.857 | 0.857 |

Discussion: ADC has been shown to correlate with liver fibrosis and inflammation [4]. Our results demonstrate that the cirrhotic liver has a lower ADC^{Total} when compared to normal, consistent with previous studies [5]. Furthermore, we established the utility of PF to diagnose cirrhosis, which is likely a reflection of the perfusional changes occurring during cirrhosis. The use of DWI has the potential to serve as a marker for liver perfusion changes and predict advanced liver disease, useful for diagnosis, prognosis and follow-up of patients with chronic liver disease. Future studies are aimed at correlating PF obtained with DWI and perfusion changes observed with dynamic contrast-enhanced imaging.

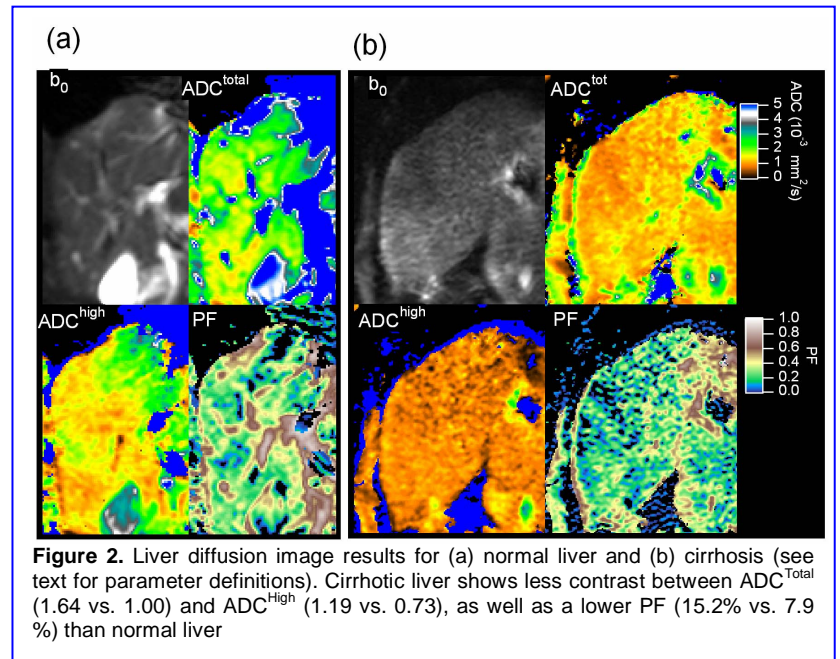


Figure 2. Liver diffusion image results for (a) normal liver and (b) cirrhosis (see text for parameter definitions). Cirrhotic liver shows less contrast between ADC^{Total} (1.64 vs. 1.00) and ADC^{High} (1.19 vs. 0.73), as well as a lower PF (15.2% vs. 7.9%) than normal liver

References

1. Girometti R, et al. JMRI 2008
2. Thoeny HC, et al. Radiology 2006
3. Hagiwara M, et al. Radiology 2008
4. Taouli B, et al. AJR 2007
5. Lewin M, et al. Hepatology 2007