

## In Vivo Detection of Colitis and Colitis-associated Early Colorectal Tumors in Mice Using Dynamic Contrast-Enhanced Magnetic Resonance Imaging

D. Mustafi<sup>1</sup>, U. Dougherty<sup>2</sup>, M. Bissonnette<sup>2</sup>, X. Fan<sup>3</sup>, G. S. Karczmar<sup>3</sup>, E. Markiewicz<sup>3</sup>, and M. Zamora<sup>3</sup>

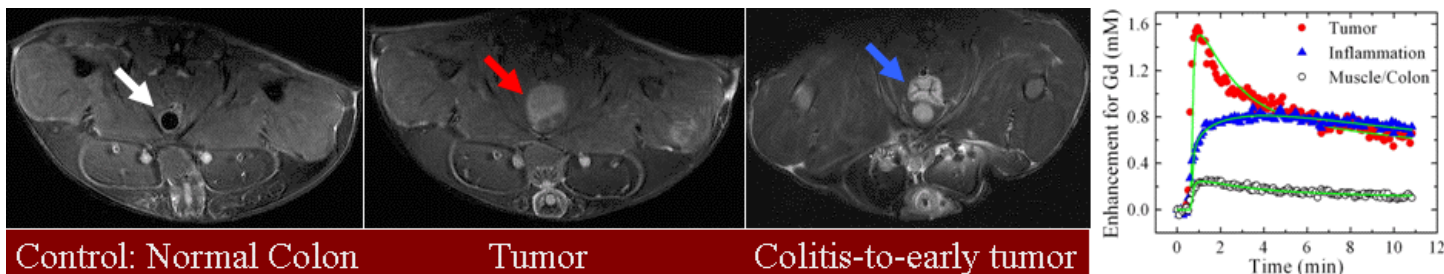
<sup>1</sup>Biochemistry & Molecular Biology, The University of Chicago, Chicago, Illinois, United States, <sup>2</sup>Medicine, The University of Chicago, Chicago, Illinois, United States, <sup>3</sup>Radiology, The University of Chicago, Chicago, Illinois, United States

**Abstract:** We have developed a high-resolution *in vivo* MRI method to assess the state of colitis and to facilitate the early detection of colitis-associated colorectal tumors in mice. From high-resolution T<sub>1</sub>/T<sub>2</sub>-weighted MR images, dynamic contrast-enhanced MRI (DCEMRI) studies with Gd-DTPA, and *in vitro* immuno-histological studies of control, colitis, tumor, and colitis-to-early colorectal tumor-bearing mice, we have demonstrated that early colorectal tumors can be detected and that the neoplastic transformation stage of chronic colitis can be distinguished from early colitis-associated cancers.

**Introduction:** Inflammatory bowel disease, including ulcerative colitis, is characterized by persistent or recurrent inflammation that can progress to colon cancer. Early detection of malignancy could improve patient prognosis as well as help target appropriate therapies. The maximal effectiveness of therapy can be achieved if properly diagnosed at an early stage. Animal models have been widely used to study the pathogenesis and potential therapies of both colitis and colon cancer associated with colitis. However, imaging methods that can evaluate colitis and early cancers in murine models have not been available. Colitis is difficult to detect and to monitor non-invasively. Herein, we report development of improved MRI methods for detecting colitis and monitoring the progression from colitis to cancer in a clinically relevant murine model.

**Methods:** For *in vivo* MR colonography at 9.4 T using control (no treatment), colitis-, colitis-to-early colorectal tumor-, and tumor-bearing mice (n=25), we used mutagen azoxymethane (AOM) and dextran sulfate sodium (DSS). This model recapitulates many of the clinical and pathological features of human colitis and cancers. Male C57Bl6/J mice were given two doses of AOM at 10 mg/kg of body weight intraperitoneally. All mice then received 2.5% DSS in their drinking water for two cycles of 5 days each: one cycle at week 2 and one at week 6, following 2 AOM injections. Mice bearing colitis-associated early colorectal tumors were imaged between 8-11 weeks after the 2-AOM/2-cycles of DSS treatments. For colitis in mice, we used only DSS treatment for 5 days. High-resolution T<sub>1</sub>/T<sub>2</sub>-weighted MR images were acquired using multiple slices with thickness of ≤1 mm. For DCEMRI, we injected ~0.12-0.14 mmol/kg of Gd-DTPA and acquired data for ~12 min. Following *in vivo* MRI studies, the mice were sacrificed, colons were harvested, and colitis and tumors were excised for immuno-histological studies.

**Results:** High-resolution T<sub>1</sub>/T<sub>2</sub>-weighted MR images showed detailed anatomical views that were corroborated with high-resolution photographs of the opened peritoneal cavities following the *in vivo* MRI studies. From MR images, colon wall thicknesses for normal colons (0.10 ± 0.02 mm) were compared to inflamed colons (0.4-1.0 mm). Colitis and early colorectal tumors were detected based on T<sub>2</sub>-weighted images. The left panel illustrates spin echo MR images of control (n=6), tumor (n=6), and colitis-to-early colorectal tumor-bearing mice (n=5). The air filled colon, the space occupying colorectal tumors, and colitis-to-early tumors are indicated in the MR images and labeled. The results from DCEMRI showed that the contrast uptake in colitis-to-early tumors is significantly different from that of colitis or muscle (or normal colon) following injection of Gd-DTPA, as shown in the plot (right panel). The two-compartment model was used to analyze dynamic data over the tumor, colitis, and muscle ROIs to obtain the rate constant for contrast media uptake ( $K^{trans}$ ) and the distribution of the contrast agent per unit volume of tissue ( $v_e$ ), as indicated by solid lines, in green, through the data points in the plot. The values of  $K^{trans}$  (in min<sup>-1</sup>) and  $v_e$  for muscle were found to be ~0.1 and ~0.2, respectively, similar to those found in the literature. The significant increase in these corresponding values for tumor and colitis, compared to that of muscle and normal colon were seen. The contrast uptake curves for the early tumor (red circles), colitis (blue triangles) and muscle areas (open circles) are shown. The values of  $K^{trans}$  (in min<sup>-1</sup>) and  $v_e$  were found to be of 0.61 and 0.82 for the colitis-to-early tumors, and 0.22 and 0.77 for the colitis, respectively, with R>0.93. MR images of tumors and colitis were also correlated with *in vitro* 2-D histological images.



**Discussion:** Based on our results with control-, colitis-, colorectal tumor-, and colitis-to-early colorectal tumor-bearing mice, we have demonstrated—for the first time—that anatomical and functional MRI studies offer the potential to discriminate chronic colitis from neoplastic transformation of early colitis-associated colorectal cancers, thus making it possible to non-invasively detect colon cancer in its very early stages. [Supported by a grant from the American Cancer Society, Illinois Div. (#08-45)]