

# Local –not global- maximal structural stress associates with vulnerable plaque features

G. Canton<sup>1</sup>, L. Dong<sup>1</sup>, H. R. Underhill<sup>1</sup>, W. S. Kerwin<sup>1</sup>, Z. Teng<sup>2</sup>, D. Tang<sup>2</sup>, B. Chu<sup>1</sup>, T. S. Hatsukami<sup>3</sup>, and C. Yuan<sup>1</sup>

<sup>1</sup>Radiology, University of Washington, Seattle, Washington, United States, <sup>2</sup>Mathematical Sciences, Worcester Polytechnic Institute, Worcester, Massachusetts, United States, <sup>3</sup>Surgery, University of Washington, Seattle, Washington, United States

## Introduction

Atherosclerosis is the result of the pathophysiological processes triggered by the complex interrelationship between genetic and epigenetic factors, such as age or gender, and structural and fluid mechanics [1]. In particular, it has been well accepted that the response of endothelial cells to the low and oscillatory shear stress induced by distinct patterns of blood flow in the carotid sinus is responsible for the local susceptibility to atherosclerosis *initiation* in this region [2]. Recent studies have suggested that *plaque rupture* may be the result of the mechanical failure of the arterial wall. Furthermore, Tang et al. [3] have suggested that *local maximal structural stress* at regions where the lipid rich necrotic core was closest to the luminal surface is a better indicator of carotid plaque susceptibility to rupture than the *global maximal stress* measured within the plaque.

Recently, multi-contrast, *in vivo* MR vessel wall imaging has found a correspondence between carotid plaque characteristics and both previous and future ipsilateral thromboembolic events [4,5]. Specifically, lesions with a large lipid-rich necrotic core, thin or ruptured fibrous cap and intraplaque hemorrhage have been identified as features indicative of lesion instability.

The *aim* of this study was to determine the association between high-risk features as measured by carotid MRI and both the *local maximal structural stress* and the *global maximal stress*.

## Methods

**Carotid Imaging:** 16 patients (age: 49-71, mean age: 67.4; 100% male) scheduled for carotid endarterectomy were imaged on a 1.5 T MRI scanner (Signa Horizon Echospeed; GE Healthcare) within one week prior to surgery. A standardized protocol [6] was utilized to obtain 3D time-of-flight (TOF), 2D T2- and PD-weighted FSE, and 2D T1-weighted pre- and post-contrast quadruple inversion-recovery [7] FSE sequences. Images were acquired in the axial plane and centered at the carotid bifurcation on the side of planned surgery. Longitudinal coverage extended for 6 slices above and below the bifurcation with a slice thickness of 2 mm. Two trained reviewers using histologically validated imaging criteria [8] interpreted each axial location by reaching a consensus opinion. In locations with a lipid-rich necrotic core present and in the absence of ulceration, custom designed software (CASCADE [9], Seattle, WA, USA) was used to identify the lumen, wall, and lipid-rich necrotic core. The minimum fibrous cap thickness was recorded. When present, the boundaries of calcification, and intraplaque hemorrhage were also identified.

**Computational Model:** The MRI-rendered lumen, wall, and plaque component contours were used to build multi-component 2D computational finite element models for each slice to obtain stress/strain distributions in the plaque. Details of the computational models can be found in [3]. Model mesh generation, solution and data post-processing were performed using finite element method commercial software (ADINA). The structural stress distribution from the numerical results was analyzed. For each slice, the average maximal principal stress (Stress-P1) around the thinnest point of the region between the lumen and the lipid-rich necrotic core was recorded as the local maximal stress (LS), assigning a zero value to the slices without lipid-rich necrotic core. The maximum value of the principal stress within the whole plaque (global maximal stress, GS) was also recorded for each slice.

**Statistical Analysis:** Pearson's correlation coefficient was used to identify associations between stress measurements and the size of the lipid-rich necrotic core and fibrous cap thickness metrics. Spearman's correlation coefficient was used to identify associations between the stress measurements and the presence/absence of calcification, and intraplaque hemorrhage.

## Results

171 axial slices from the 16 subjects had sufficient image quality for analysis. The results of the statistical analysis are summarized in Table 1. Both local maximal stress (LS) and global maximal stress (GS) were associated with the size of the lipid-rich necrotic core (LRNC), but a stronger correlation was evident for LS. Both stress parameters were strongly associated with the presence of calcification. The local maximal stress (LS) was significantly correlated to both the presence of intraplaque hemorrhage (IPH) and the minimum fibrous cap thickness (MT, Fig. 2). GS, however, was not significantly associated with either intraplaque hemorrhage or fibrous cap thickness.

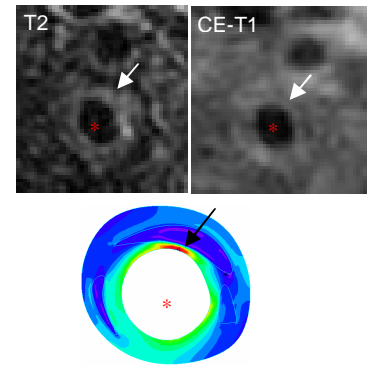
## Discussion

Prospective studies have shown that thin fibrous cap and intraplaque hemorrhage are significantly associated with the development of cerebrovascular complications [5]. Our findings indicate that lesions with intraplaque hemorrhage and/or a thin fibrous cap are susceptible to an increase in local maximal stress. As such, localized elevation in structural stress may be associated with an increased propensity towards fibrous cap rupture – an event associated with thrombogenesis. Figure 2 offers compelling evidence for this hypothesis since an increase in stress was associated with a decrease in the fibrous cap thickness. The poor or absent association between global maximal stress and high-risk plaque features suggests that lesions more prone to rupture may be better discriminated by conditions at the wall/lumen interface more so than the overall plaque architecture.

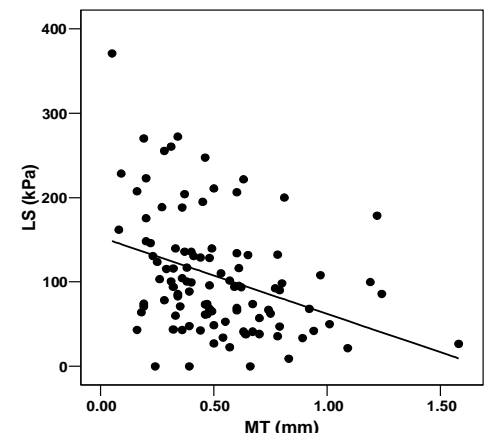
## Conclusion

In carotid atherosclerotic lesions with a lipid-rich necrotic core, *local maximal stress* may identify the plaque at risk of fibrous cap rupture. Longitudinal studies are necessary to determine if local maximal stress predicts future fibrous cap rupture and to establish the stress threshold values for at-risk lesions.

**References:** 1. Ku DN. *Ann Rev Fluid Mech* 1997; 29:399–434. 2. Slager CJ, et al. *Nat Clin Prac Card* 2005;2:401-407. 3. Tang D, et al. *Ann Biomed Eng* 2005;33:1789-1801. 4. U-King-Im JM, et al. *J Neurol Neurosurg Psychiatry* 2008;79:905-912. 5. Takaya N, et al. *Stroke* 2006; 37:818-823. 6. Yuan C, et al. *NMR Biomed* 2006;19:636-654. 7. Yarnykh, et al. *Magn Reson Med* 2002;48:899-905. 8. Saam, et al. *ATVB* 2005;25:234-239. 9. Kerwin W, et al. *Top Magn Reson Imag* 2007;18:371-378.



**Figure 1.** White arrows indicate the location of a necrotic core in the MR images. A black arrow indicates the location of local maximal stress in the corresponding wall stress distribution band plot. The red star indicates the lumen.



**Figure 2.** Slice-based analysis of local maximal stress (LS) and minimum fibrous cap thickness (MT).