

Simultaneous EEG-CBV (Electroencephalography – Cerebral Blood Volume) measurements of epileptic spikes

M. Negishi¹, M. Qiu¹, and R. T. Constable^{1,2}

¹Diagnostic Radiology, School of Medicine, Yale University, New Haven, CT, United States, ²Neurosurgery, School of Medicine, Yale University, New Haven, CT, United States

Background: Simultaneous EEG and VASO (Vascular Space Occupancy) imaging can be used to characterize CBV (cerebral blood volume) changes during interictal epileptic discharges (IED's). However, the VASO sequence causes more RF pulse artifacts in the EEG than spin-echo or gradient-echo functional MRI (fMRI) sequences, because the global inversion pulses in the VASO sequence require higher RF power than slice selection pulses. In a previous research, we found that most RF pulse artifacts are generated at the interface between carbon and metal components. In this research, we compared the RF artifacts generated by different types of carbon wire to metal wire connections. We also conducted a feasibility study of simultaneous EEG-CBV measurements.

Method: (1) In a phantom study, three types of carbon-to metal contacts were compared, namely (a) copper crimp pins (b) copper crimp pins and silver epoxy glue, and (c) brass nuts and bolts with brass washers to sandwich the ends of carbon wires. (2) To show the feasibility of simultaneous EEG and VASO recording, we recorded CBV change from four localization related epilepsy patients (17 to 50 years old) with frequent IED's after written consent, and compared the IED related CBV changes with IED related BOLD changes acquired in separate runs. Each patient underwent four alternate runs (eight in total) of simultaneous EEG-BOLD and simultaneous EEG-CBV measurements during the resting state. The BOLD images were obtained in a 3T scanner using an echo-planer imaging (EPI) sequence (TR/TE=1550/50 ms, 25 6mm oblique axial slices). The CBV images were obtained in the same scanner using a Global Inversion Cycling VASO sequence (TR=3000 ms, 21 6mm axial slices). BOLD images were subject to the generalized linear model analysis to obtain a IED related BOLD activation map for each patient. To compare BOLD and CBV timecourses, suspected ROI (region of interest) was defined using the BOLD activation map, and average BOLD and CBV signal timecourses at the ROI around the IED was computed for each patient.

Result: (1) Crimp pin connections (with or without silver epoxy glue) resulted in about 200 microvolts RF artifact, whereas the RF artifact was invisible with bolt and nut connections (Figure 1). This is consistent with our previous observation that loose carbon fiber ends are the cause of RF pulse artifact. (2) In all patients, significant BOLD activation was found at concordant loci with clinical EEG reading. In all patients, average EPI (BOLD) and VASO (negative CBV) timecourses showed positive and negative responses to the IED's, respectively (Figure 2, each normalized at the peak intensity).

Conclusion: High pressure contacts using a nut and a bolt with washers resulted in the smallest RF pulse artifacts. It was shown that simultaneous EEG-CBV measurement is feasible.

Acknowledgement: This research was partly supported by NIH R01-NS47605.

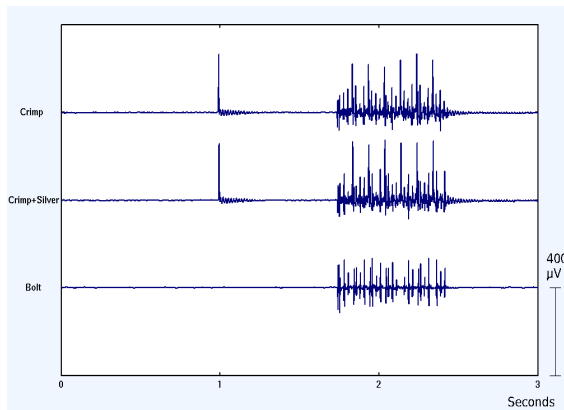


Fig. 1. MRI artifacts measured with different EEG connections

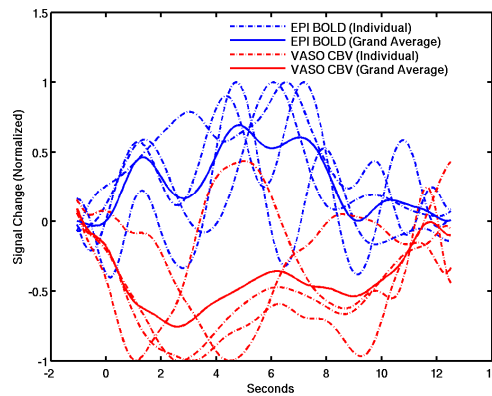


Fig. 2. Averaged BOLD and CBV timecourses

References:

- Lu H, van Zijl PCM, Hendrikse J, Golay X. Multiple acquisitions with global inversion cycling (MAGIC): a multislice technique for vascular space occupancy dependent fMRI. *Magn Reson Med* 2004;51:9–15.
- Negishi M, Pinus BI, Pinus AB, Constable RT. Origin of the radio frequency pulse artifact in simultaneous EEG-fMRI recording: Rectification at the carbon-metal interface. *IEEE Trans Biomed Eng* 2007;54(9):1725-27.
- Scouten A, Constable RT. Applications and limitations of whole-brain MAGIC VASO functional imaging. *Magn Reson Med* 2007;58(2):306-15.