

DTI is useful for early diagnosis of MSA, separating from Parkinson's disease: Evidence for subclinical detection of cerebellar pathology

S.-Y. Park¹, S.-H. Oh¹, C.-S. Lee², S.-J. Kim³, J.-S. Kim⁴, Y.-B. Kim¹, and Z. Cho¹

¹Neuroscience Research Institute, Gachon University of Medicine and Science, Incheon, Korea, Republic of, ²Institute for Parkinson's Research, Ulsan University College of Medicine, Seoul, Korea, Republic of, ³Department of Radiology, Asan Medical Center, Seoul, Korea, Republic of, ⁴Department of Nuclear Medicine, Asan Medical Center, Seoul, Korea, Republic of

Introduction

Multiple system atrophy (MSA) is a sporadic neurodegenerative disorder, characterized by autonomic dysfunction with varying severity of cerebellar ataxia and parkinsonism. Based on predominant symptoms, either cerebellar ataxia or parkinsonism, MSA is classified into two subtypes, MSA-c and MSA-p, respectively. It is notoriously difficult to distinguish MSA-p from PD, particularly in the early stage, because MSA-p may show parkinsonism that responds to dopamine replacement therapy. DTI is a new MRI technique that provides a way of estimating brain fiber structures using water diffusion properties. It offers superior pathological specificity compared with the conventional MRI. Recently, several studies report that DTI MR findings may be useful to separate MSA from PD. Apparent diffusion coefficient (ADC) reflects movements of water molecules within tissue, and increases when neural structure is destroyed. In the present study, we explored clinical significance of DTI in the diagnosis of MSA.

Methods

We studied 19 MSA (6 MSA-p, 4 MSA-mixed, 9 MSA-c), 7 PD and 14 normal subjects. The severity of parkinsonism and cerebellar ataxia of MSA patients were assessed by using UPDRS III and the scale for the assessment and rating of ataxia (SARA), respectively. We used a 1.5T MR scanner (Avanto, Siemens, Germany). DTI were obtained by a single-shot echo planar imaging (EPI) sequence (TR/TE = 6400/86ms, b = 900s/mm², 30 directions, FOV = 230mm, matrix = 128x128, slice thickness = 3mm, averaging = 2, bandwidth = 1302Hz/Px). Diffusion tensor tractography was performed by using

MedINRIA fiber tracking software. We measured changes of apparent diffusion coefficient (ADC) by a region-of-interest (ROI) analysis in the middle and superior cerebellar peduncles and in the anterior and posterior putamina. We compared ADC values of each brain region in patients with MSA, patients with PD, and normal subjects by means of ANOVA. For correlation analysis, ADC values of each region were regressed on SARA or UPDRS scores.

Results

Fig. 1 shows diffusion tensor tractography of patients with MSA, patients with PD, and normal subjects in the middle and superior cerebellar peduncles. Fig 2 shows that ADC values of the middle, but not superior, cerebellar peduncle were significantly different between groups (p<0.0001), higher than normal in the MSA-c group, and to a lesser degree, in the MSA-p group (MSA-c = MSA-mixed > MSA-p > PD = Normal). In contrast, ADC values of the posterior, but not anterior, putamen showed significant group differences (p<0.0001), higher than normal in the MSA-p group, but not in the MSA-c or PD group (MSA-p = MSA-mixed > MSA-c = PD = Normal). Within the MSA group, correlation analysis showed that: (i) SARA scores correlated significantly with ADC of the middle cerebellar peduncle (p = 0.010, r = 0.641); (ii) UPDRS III scores showed marginally significant correlation with ADC of the posterior putamen (p = 0.053, r = 0.525).

Conclusions

We showed that DTI detected selective lesions in the middle cerebellar peduncle and/or posterior putamen in MSA patients. We also presented evidence that the increase in ADC value of the middle cerebellar peduncle precedes the appearance of cerebellar ataxia. These observations suggest that DTI can separate MSA-p from PD even when the patient shows parkinsonism only. We propose that DTI can be a valuable tool for the diagnosis of MSA.

References

- [1] C.R.V.Blain et al., Neurology 2006 ;67 :2199-2205
- [2] C. Nilsson et al., Neuroradiology 2007;49;111-119,
- [3] Michael F.H. Schocke et al., NeuroImage 2004;21;1443-1451

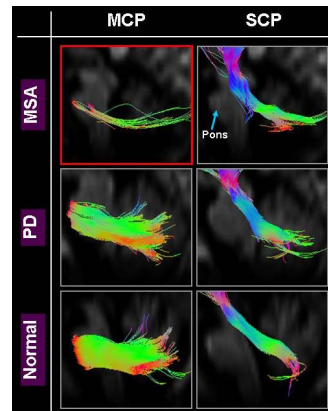
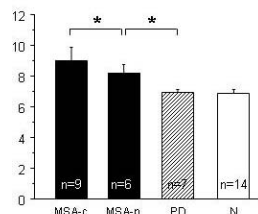
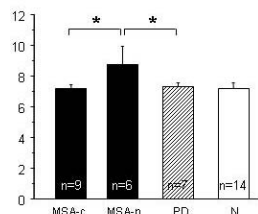


Fig 1. The MSA group showed significant atrophy in the middle cerebellar peduncle, but not in the superior cerebellar peduncle. The PD group did not show significant changes in the middle and superior cerebellar peduncles.

ADC of the Middle Cerebellar Peduncle



ADC of the Posterior Putamen



Correlation of SARA Scores with ADC of Middle Cerebellar Peduncle

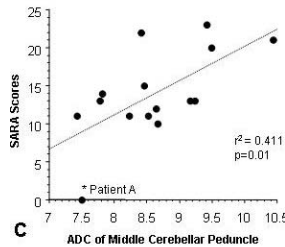


Fig 2. A. ADC values of the middle cerebellar peduncle showed significant group differences (p<0.0001): MSA-c > MSA-p > PD = Normal. B. ADC values of the posterior putamen showed significant group differences (p<0.0001): MSA-p > MSA-c = PD = Normal. The MSA-mixed group (n=4) is not shown for the clarity. Error bar = 1 SD. C. SARA scores that assess the severity of cerebellar ataxia correlate significantly positively with ADC values of the middle cerebellar peduncle. *Patient A showed DOPA-responsive parkinsonism and was initially diagnosed as PD. She showed increased ADC in the middle cerebellar peduncle. [¹⁸F]FDG-PET showed reduced FDG uptake in the putamen and the cerebellum, which is consistent with MSA. *n=16 (Three cases were missing due to the absence of SARA scores).

Correlation: SARA Scores vs ADC of MCP

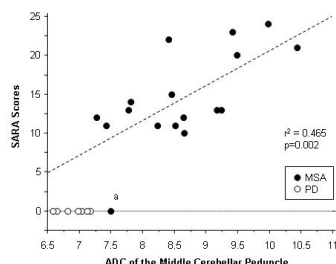


Fig 3. SARA scores correlate significantly positively with ADC values of the middle cerebellar peduncle. Patient A, who was clinically diagnosed as PD, showed high ADC values in the middle cerebellar peduncle.

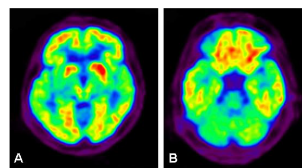


Fig 4. [¹⁸F]FDG-PET of the patient A showed the pattern of MSA: (A) reduced FDG uptake in the right putamen, more so posteriorly; (B) mild reduction of FDG uptake in the right cerebellar hemisphere.