

Measurement of the increase in vessel size induced by a vascular disrupting agent in orthotopic prostate tumours using vessel size imaging

S. Walker-Samuel¹, J. K. Boulton¹, L. D. McPhail¹, and S. P. Robinson¹

¹Cancer Research UK Clinical Magnetic Resonance Research Group, Institute of Cancer Research, Sutton, Surrey, United Kingdom

Introduction

Vascular disrupting agents (VDAs) have been developed to exploit differences between normal and tumour vasculature, with the aim of selectively disrupting and destroying the tumour endothelium, whilst leaving normal blood vessels relatively unaffected [1]. ZD6126 (N-acetylcolchicinol-O-phosphate) is a VDA shown to have significant anti-tumour activity against a broad range of human xenografts in rodent model systems and human tumour vasculature [2,3]. This class of agents typically does not induce tumour regression, so imaging biomarkers of functional vasculature are required to evaluate tumour response. The aim of this study was to assess tumour vessel size index (VSI, a weighted average measure of vessel diameter), fractional blood volume (ξ) (determined *in vivo* by susceptibility contrast MRI), and the apparent diffusion coefficient (ADC), to provide non-invasive imaging biomarkers of response to ZD6126 in orthotopic PC3 prostate tumours. Use of the fluorescent endothelial stain Hoechst 33342 also enabled the qualification of VSI and blood volume measurements. These parameters were estimated using a novel, robust Bayesian maximum *a posteriori* approach [4].

Methods and Materials

Study design: Orthotopic PC3 prostate tumours were propagated in 6 nude NCr mice. At 20 days following inoculation, VSI, ξ and ADC of each of the tumours was estimated according to the acquisition and analysis protocol described below. Immediately following this scan, ZD6126 was administered (200mg/kg i.p.). At 24 hours following this dosing, each mouse underwent a second MR scan, after which Hoechst 3342 (a fluorescent endothelial stain) was administered as a terminal experiment. A second cohort of 6 nude mice was solely administered Hoechst 33342 at 20 days in order to provide a pre-treatment control.

Acquisition and analysis: All measurements were undertaken on a 7T Bruker horizontal bore scanner. The change in R_2^* and R_2 induced by USPIO (ferumoxtran-10, Sinerem, Guerbet) and the ADC were used to estimate VSI, according to the approach described by Troprès et al [5]. R_2^* and R_2 were estimated from data acquired using a multi-gradient echo sequence (TR=200ms, 8 echoes ranging from 6 to 28ms) and multi-spin echo sequence (TR=3000ms, 12 echoes ranging from 12 to 144 ms), respectively. ADC values were estimated from a diffusion-weighted spin-echo sequence (6 b-values from 6 to 500 s/mm², TR=1000ms). Parameter estimation was performed using a novel Bayesian maximum *a posteriori* algorithm which took into account the Rician distribution of noise in magnitude MR data in order to provide unbiased parameter estimates [4]. It also provided the ability to identify non-enhancing (non-perfused) pixels or parameter estimates with a large associated uncertainty, thereby facilitating their removal from the VSI calculation. Furthermore, the tumour enhancing fraction (TEF, the fraction of tumour pixels that significantly enhanced due to USPIO, with $p < 0.1$) was determined.

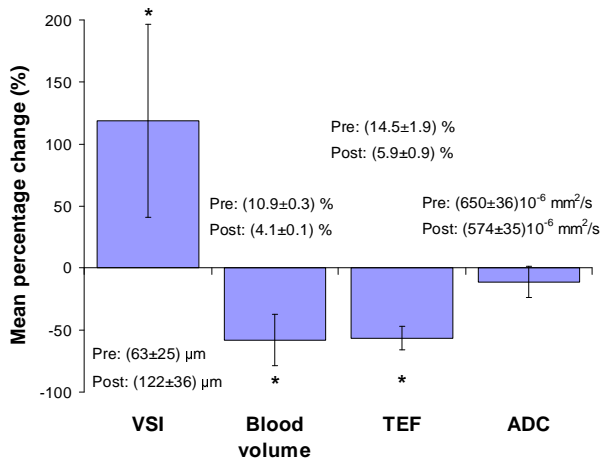


Figure 1: Percentage changes in each MR biomarker at 24 hours following administration of ZD6126 ((* implies $p < 0.05$).

Measurements of vessel diameter were performed on Hoechst-stained whole-tumour sections. These were converted into VSI values (VSI_{histo}) using an approach described by Troprès et al. [6]. TEF and ξ estimates were compared with measurements of Hoechst perfused area (HPA).

Results and Discussion

Mean tumour volume was $581 \pm 116 \text{ mm}^3$ pre-ZD6126 and $644 \pm 141 \text{ mm}^3$ at 24 hours after treatment. The change in tumour volume was not significant ($p > 0.1$). Figure 1 shows the percentage change in each MR parameter following treatment with ZD6126. The mean VSI prior to therapy was $65 \pm 25 \mu\text{m}$, which agreed well with the Hoechst VSI measurement of $67 \pm 6 \mu\text{m}$ in control tumours (see Figure 2). This value is larger than the 10-30 μm typically found in ectopic (subcutaneous) tumour xenograft models. Following treatment, the mean VSI, predominantly determined from the tumour periphery, significantly increased to $122 \pm 36 \mu\text{m}$ ($p < 0.05$), which again agreed well with the Hoechst VSI measurement of $137 \pm 9 \mu\text{m}$. This excellent accordance is likely to be due in part to the robust approach taken to parameter estimation, which has been shown not to suffer from the over-estimation of VSI typically associated with this type of experiment [4,6]. TEF decreased significantly from $14.5 \pm 1.9\%$ to $5.9 \pm 0.9\%$ ($p < 0.05$) and was accompanied by a significant decrease in ξ (blood volume) from $10.9 \pm 0.3\%$ to $4.1 \pm 0.1\%$ following ZD6126 treatment (see Figure 1). Both of these results agreed well with measurements of HPA, which displayed a significant difference between control and treated tumours ($21.6 \pm 7\%$ and $5.2 \pm 1.1\%$, respectively). No significant change in ADC was observed.

Conclusions

Non-invasive VSI MRI using a novel and robust parameter estimation procedure therefore revealed: i) the presence of large vessels in orthotopic PC3 prostate tumours, relative to those typically found in ectopic tumours; ii) a significant increase in vessel calibre and overall reduction in blood volume at 24 hours after administration of the vascular disrupting agent ZD6126. These estimates agreed well with equivalent histological measures.

Acknowledgements: This work was supported by Cancer Research UK (C1060/A808/G7643 and C16412/A6269), NHS funding to the NIHR Biomedical Research Centre and The Royal Society.

References: 1) Siemann DW *et al*, Clin Cancer Res, 11, 416-420, 2005. 2) Blakey DC *et al*, Clin Cancer Res, 8, 1974-1983, 2002. 3) Davis PD *et al*, Cancer Res, 62, 7247-7253, 2002. 4) Walker-Samuel *et al*, ISMRM Cancer Workshop, Nice, 2008. 5) Troprès *et al*, Magn Reson Med, 45(3):397-408, 2001. 6) Troprès *et al*, Magn Reson Med, 51(3):533-41, 2004.




Figure 2: False-colour images of Hoechst stained tumour sections in a control (left) and treated tumour (right), with vessel diameter measurements overlaid. Dark regions represent perfused blood vessels.

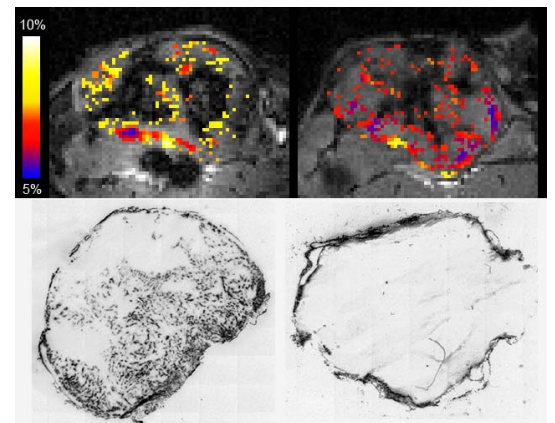


Figure 3: Top: Example blood volume (ξ) maps pre- and post-ZD6126 (left and right, respectively). Bottom: Representative whole-tumour Hoechst-stained sections. Both sets of images illustrate the acute reduction in blood volume induced by ZD6126.