

Comparison of CBF measurement by ASL and SPECT in Patients with Internal Carotid Artery Stenosis.

Y. Uchihashi¹, K. Hosoda¹, I. Zimine², A. Fujita¹, S. Inoue¹, H. Aihara¹, H. Kawamitsu³, N. Aoyama³, H. Aoki³, M. Fujii³, and E. Kohmura¹

¹Dept. of OrganTherapeutics, Neurosurgery, Kobe university graduate school of Medicine, Kobe, Hyogo, Japan, ²Philips Healthcare Japan, ³Dept. of Radiology, Kobe university graduate school of Medicine, Kobe, Hyogo, Japan

INTRODUCTION: Hemodynamic assessment of patients who have steno-occlusive cerebrovascular disease plays an important role for decision making and planning of surgical interventions. In this field, SPECT is currently the modality of choice, but faster and less invasive techniques are highly desirable. Arterial spin labeling (ASL) is emerging as clinically promising technique for non-invasive perfusion measurement. However there are still concerns about reliability of CBF quantification. Recently, ASL implementation called QUASAR has been proposed [1]. It combined several ideas from other ASL techniques into a single sequence allowing time-efficient data acquisition at multiple inversion times and introduced novel model-free and user independent CBF quantification method. A large multi-center study showed very good CBF reproducibility in healthy volunteers [2]. The purpose of this study was to compare CBF obtained by QUASAR method and by SPECT in patients with internal carotid artery stenosis.

METHODS: Fourteen healthy volunteer (7 men,7 women, mean age±S.D. is 45.1±13 years. Range is 27-60years.) and 34 patients (30 men, 4 women; mean age±S.D. is 71.9±5.7 years. Range is 59-83years.) with internal carotid artery stenosis were recruited to participate in ASL-SPECT comparative study with approval of the local ethics committee. MRI examination was performed on a 3T clinical scanner (Philips Achieva R2) within 3 days from SPECT. The protocol included two ASL scans, before and after injection of ACZ, with a 3D whole brain gradient echo image acquired in between. For ASL, QUASAR sequence was used with the following parameters: FOV=240 mm, matrix=64x64, 7 slices (6mm, 2mm gap), TR/TE/ΔTI/ TI₁=4000/22/300/40 ms (13 time points), FA=35°/11.7°, SENSE=2.5, 82 averages (48 @ V_{enc}=4cm/s, 24 @ V_{enc}=∞, 10 @ low flip angle). 25 patients received an administration of acetazolamide to examine cerebrovascular reactivity (CVR). Segmentation map obtained by using T1-weighted image. The segmentation map is applied to the CBF data giving Gray Matter CBF quantification. In all patients, ¹²³I-MP-SPECT was also performed before and after injection the same dose of Acetazolamide (ACZ) using dual head camera (Tohshiba, ECAM) as previously reported [3].

For CBF comparison, ASL and SPECT data was first registered using flirt tool from the FSL package [4]. To do so, a rigid transformation to align SPECT to skull stripped 3D was found. It was then combined with off-center differences between 3D and ASL scan geometries in order to bring SPECT into ASL coordinates space. So far, regional CBF (rCBF) analysis was performed in 14 subjects who have no major infarction on routine MRI scan. Custom viewing software (IDL 6.1) was used to draw ROIs on registered SPECT slices and copy them onto ASL slice. Ten oval ROIs were drawn per a slice, which consist of bilateral frontal, temporal, occipital, and cerebral border-zones.

RESULTS: In all volunteers and patients, routine anatomical MRI scans and CBF measurement by QUASAR were performed within an hour. In healthy volunteers, mean gray matter CBF and CVR obtained by QUASAR (40.2±6.9 ml/100g/min, 55.9±28.9%, respectively, Figure 1)) was in accordance with that of previously reported [5]. In comparison study, QUASAR demonstrated similar results as SPECT regarding CBF assessment under different conditions (Figure 2). rCBF measured by QUASAR was significantly correlated with that measured by SPECT (r=0.83) (Figure 3). CBF measured by QUASAR tend to be overestimated in higher CBF regions, especially in CVR study compared with that measured by SPECT.

CONCLUSION: ASL (QUASAR) demonstrates adequate CBF values in healthy volunteers. CBF measurements obtained from ASL have good agreement with SPECT in patients with internal carotid artery stenosis. We should pay attention to the properties of ASL to make decision in patients with cerebrovascular diseases.

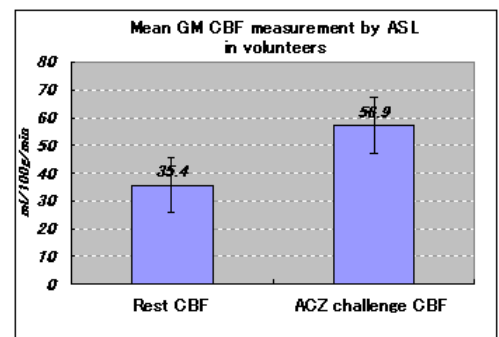


Fig.1 Mean gray matter CBF obtained by ASL in volunteers: Rest and Acetazolamide challenge

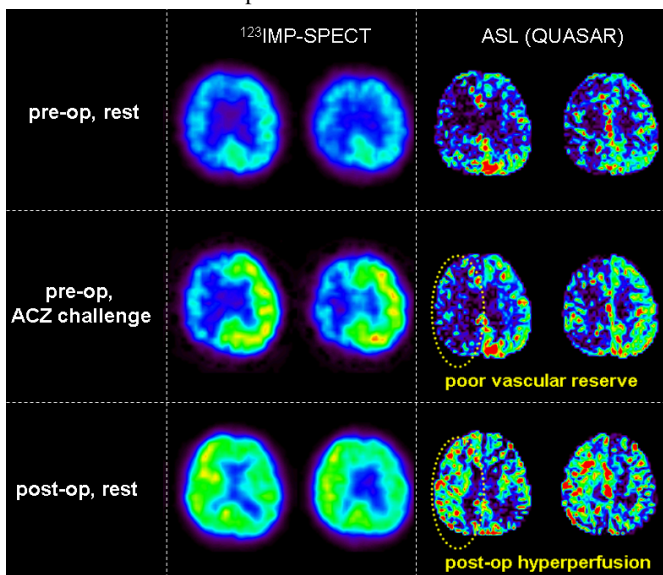


Fig.2: CBF maps of a patients with severe right ICA stenosis in different conditions. Both ASL and SPECT demonstrated preoperative poor cerebral perfusion, poor vascular reserve, and postoperative hyperperfusion phenomena in affected side.

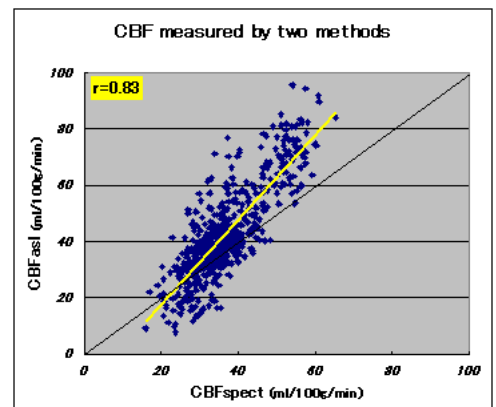


Fig. 3: Comparison of rCBF by ASL and SPECT. CBF obtained from ASL have good agreement (r=0.83) with that from SPECT. In higher CBF region, ASL tends to overestimate CBF value compared with SPECT.

REFERENCES: [1] Petersen ET et al., MRM 55:219 (2006) [2] Petersen ET et al., Proc. ISMRM p.191 (2008) [3] Nishizawa S et al., Eur J Nucl Med Mol Imaging 30(7):943-50 (2003) [4] Jenkinson M et al., Neuroimage 17:825(2002) [5] Hosoda K et al., Stroke 32:1567-1573(2001)