

# Coil System for Optimal MR Mammography and MR-Guided Intervention

B. M. Kaufman<sup>1</sup>, Y. Hamamura<sup>1</sup>, A. Menon<sup>1</sup>, and J. Jevtic<sup>2</sup>

<sup>1</sup>MR, Invivo, Pewaukee, WI, United States, <sup>2</sup>Engineering, Milwaukee Area Technical College, Milwaukee, WI, United States

**Objective:** Breast MRI has been proven as a valuable adjunct to conventional mammography for the detection and staging of breast cancer. The sensitivity and specificity of breast MRI range from 94%-100% and 37%-97% respectively. Biopsy remains the standard for proving malignancy, so in accordance with the ACR Practice Guidelines for Performance of Magnetic Resonance Imaging of the Breast, patients whose breasts are scanned with MRI should also be able to undergo biopsy with MRI-guidance. Our purpose was to develop a coil system for imaging the breasts and performing MRI-guided interventions.

**Materials and Methods:** The breast coil system has two coil modules that are diagnostic and interventional. Since diagnostic studies and interventional procedures are not done in a single exam, using two different RF coils dedicated these two imaging protocols maximizes the benefit of MRI breast imaging. The diagnostic coil is dedicated to provide high SNR in diagnostic imaging and high parallel imaging factor to increase time resolution in dynamic imaging. Focusing on diagnostic usage, its closed cup design made it possible to lay out RF coil elements closer to the imaging volume, which provides significantly high image SNR (Fig.A). The interventional coil has maximum capability of accessing tissue for procedures to be performed from three approaches: lateral, medial or cranial while maintaining the conventional breast coil image quality (Fig.B).

**Results:** A phantom SNR profile in A-P axis along the cup center is shown in Figure C. The position 0 mm represents the top surface of the coil. The result showed the diagnostic coil has up to 200% of SNR than the interventional which makes possible to achieve sub-millimeter (0.6 x 0.6 x 0.6) spatial resolution with sub-minute temporal resolution (Fig.D). This enables detection of very small structures within the breast parenchyma and surrounding tissue. In 4-24% of cases if a known lesion exists and a bilateral MRI is performed occult contralateral disease can be detected. It can then be proven early with MRI-guided biopsy performed on the 7-channel coil.

**Conclusions:** The increased SNR and high temporal and spatial resolution of the diagnostic 16-channel coil improve small structure detection. The interventional, 7-channel coil enables percutaneous procedures to be performed from three approaches: lateral, medial or cranial. In patients with synchronous cancer detected at MRI, treatment can be altered, sparing them multiple courses of therapy. This also lessens the burden on the health care system by allowing planning of the appropriate treatment a single time.

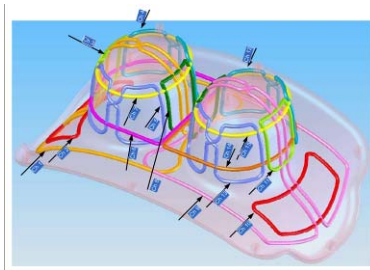


Fig. A. Coil element layout of the diagnostic 16 channel coil. The elements are aligned to make parallel imaging possible in all directions

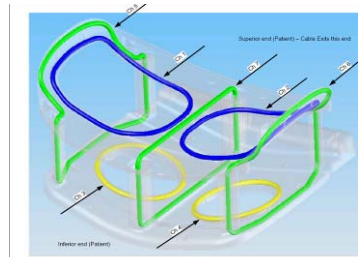


Fig. B. Coil element layout of the interventional 7 channel coil. The elements are designed to allow maximum interventional access.

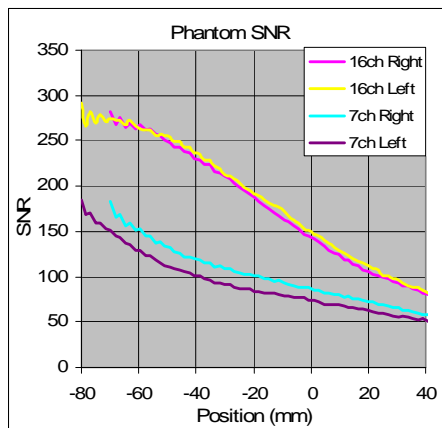


Fig. C. A phantom SNR profile in A-P axis along the cup center acquired with a 3T system. The diagnostic coil showed up to 200% of SNR than the interventional coil.

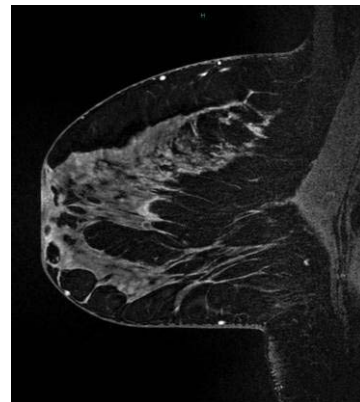


Fig. D. High resolution isotropic 0.6 x 0.6 x 0.6 mm thick 3D sagittal acquired in under 1 minute.