

Significantly better local prostate cancer staging performance with T2-weighted 3T endorectal coil MR imaging compared with real-time gray-scale tissue harmonic imaging TRUS

S. W. Heijmink¹, T. W. Scheenen¹, T. Hambroek¹, C. A. Hulsbergen-van de Kaa², J. A. Witjes³, and J. O. Barentsz¹

¹Radiology, Radboud University Nijmegen Medical Centre, Nijmegen, Gelderland, Netherlands, ²Pathology, Radboud University Nijmegen Medical Centre, Nijmegen, Gelderland, Netherlands, ³Urology, Radboud University Nijmegen Medical Centre, Nijmegen, Gelderland, Netherlands

Introduction

In 2008, an estimated 186,320 new cases of prostate cancer will be diagnosed in the United States alone. With an estimated one in every four new cases of cancer in men being prostate cancer, the disease burden is considerable [1]. Accurate local disease staging is a necessity for deciding a patient's treatment, since a patient having locally advanced cancer is no longer a candidate for curative surgical removal of the prostate gland. A large number of studies have been performed using either transrectal ultrasound (TRUS) or magnetic resonance (MR) imaging for local staging. However, no contemporary study has been performed directly comparing both modalities using state-of-the-art technology. Therefore, the purpose of our study is to compare the diagnostic accuracy of local prostate cancer staging between real-time tissue-harmonic imaging gray-scale TRUS and T2-weighted 3 tesla (T) endorectal coil (ERC) MR imaging using whole-mount histopathology as standard of reference.

Materials and methods

Patients – In a prospective study, from November 2005 to December 2006, after written informed consent, 41 consecutive patients with biopsy-proven prostate cancer underwent preoperative TRUS and MR imaging.

TRUS – All examinations were performed on an Aplio (Toshiba Medical Systems, Japan) ultrasound machine. TRUS probe frequency was 7 MHz. Gray-scale imaging was acquired in tissue-harmonic imaging setting. An axially oriented 60-second sweep through the prostate covering the entire gland and seminal vesicles from apex to base was performed.

MR imaging – All imaging was performed on a 3T whole-body scanner (TRIO TIM, Siemens Medical Solutions). An ERC (Medrad®, USA) was inserted and subsequently filled with 50 cc of fluid. Bowel movement was suppressed by intramuscular injection of 1 mg glucagon (Glucagen®, Novo Nordisk A/S) immediately prior to scanning. After localizing series to check and possibly change the ERC position, T2-weighted fast spin-echo images (TR/TE 5000/153 ms, hyperechoes [2], voxel size: 0.26 x 0.26 x 2.50 mm³, interslice gap: 0.5 mm) in the sagittal, coronal, and axial plane were obtained.

Data analysis – All data sets were anonymized. Approximately one year after acquisition, two readers with different levels of experience independently read all data sets. Reader A had 4 years of experience in prostate TRUS and MR imaging, while reader B had 2 years of experience in both. Image quality and the presence of artifacts influencing interpretation were scored by both readers. In case of poor image quality or severe artifacts, a patient was excluded from the study. TRUS and MR imaging sets were read separately with one-month intervals in between. The disease stage was scored from definitely organ-confined (stage T2) disease to definitely locally advanced (stage T3) disease on a five-point probability scale.

Standard of reference – All included patients underwent laparoscopic radical prostatectomy within 4 weeks after imaging. All specimens were staged according to the 2002 TNM staging classification by a pathologist with 10 years of experience.

Statistical analysis – Receiver-operator characteristic (ROC) analysis was performed and the areas under the ROC curve (AUC) were determined. By dichotomizing the results sensitivity and specificity were calculated. *P* < .05 was considered statistically significant.

Results

Patients – After exclusion of six patients (two due to gross extraprostatic spread, one due to lymph node spread, and three due to insufficient image quality or presence of artifacts), 35 patients were included. Mean age was 60 years (range: 43-69), mean PSA level was 7.7 ng/ml (range: 3.6-24.6), median Gleason biopsy score was 6 (range: 5-9). Twelve patients had stage T3 disease, while 23 patients had stage T2 disease.

ROC analysis (see Figure 1, Table) – For readers A and B the AUC of MR imaging staging (0.95 and 0.82, respectively) was significantly higher than that of TRUS (0.76 and 0.55) (example, Figure 2).

Sensitivity and specificity (see Table) – For reader A, the sensitivity for detecting locally advanced disease significantly improved from 50% (5/12) with TRUS to 100% (12/12) with 3T ERC MR imaging. The sensitivity of reader B increased from 33% (4/12) to 75% (9/12) (*P*>0.05). Specificity for TRUS and MR imaging remained equally high for both readers.

Discussion and conclusions

Both readers achieved a significantly higher diagnostic accuracy with 3T ERC MR imaging compared with TRUS. The sensitivity of detecting locally advanced disease was increased for both readers. For the most experienced reader it increased significantly. For both imaging modalities staging performance improved with increased experience. In clinical practice, state-of-the-art 3T ERC MR imaging ought to be the preferred modality for detecting locally advanced disease. The main advantage of TRUS may be its high specificity, providing usefulness in preselecting patients for MR imaging.

References

(1) Jemal A, et al. CA Cancer J Clin 2008;58:71-96. (2) Hennig J, et al. Hyperechoes. Magn Reson Med 2001;46:6-12.

Table: AUC, accuracy, sensitivity and specificity of prostate cancer staging [* *P* <0.05]

	Reader A (4 years experience)		Reader B (2 years experience)	
	TRUS	MRI	TRUS	MRI
AUC	0.76	0.95 *	0.55	0.82 *
Accuracy	28/35 (80%)	33/35 (94%)	21/35 (60%)	26/35 (74%)
Sensitivity	6/12 (50%)	12/12 (100%) *	4/12 (33%)	9/12 (75%)
Specificity	22/23 (96%)	21/23 (91%)	17/23 (74%)	17/23 (74%)

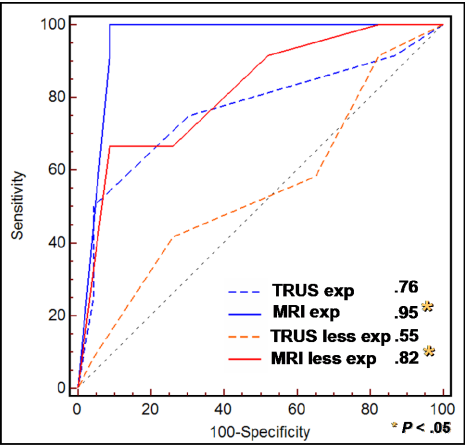


Fig.1: ROC curves and AUCs of local prostate cancer staging for TRUS and MR imaging for two readers with different levels of experience. MR imaging had a significantly higher AUC than TRUS for both readers.

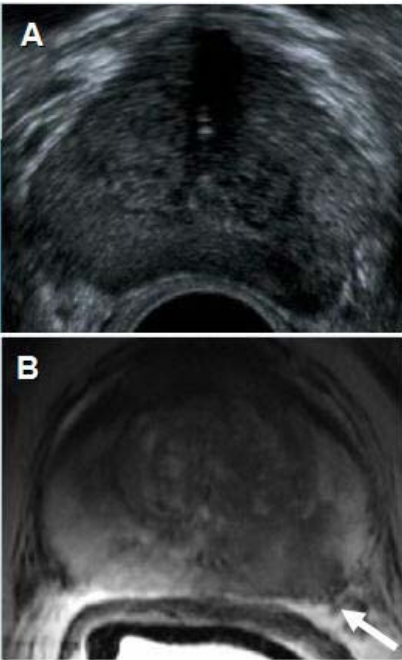


Fig.2: Example of a (A) TRUS and (B) 3T ERC MR image of stage T3 prostate cancer in the left lateral peripheral zone (arrow). This case with histopathologically proven minimal capsular penetration was only correctly diagnosed on MR imaging.