

Longitudinal study of ¹H MRS of lactate upon treatment in a non-Hodgkin's lymphoma patient

S. C. Lee¹, E. A. Mellon¹, H. Poptani¹, E. J. Delikatny¹, and J. D. Glickson¹

¹Dept of Radiology, University of Pennsylvania, Philadelphia, PA, United States

INTRODUCTION

Previously we've shown in a human lymphoma xenograft model that in vivo MRS detected lactate is a very early marker of response to either CHOP or R-CHOP therapy [1,2]. Last year we've presented clinical scanner version of the lactate detection sequence (Hadamard-SelMQC-CSI) in the phantom studies [3]. This year we applied the clinical scanner version of the lactate sequence to monitoring early response to R-CHOP therapy in a non-Hodgkin's lymphoma patient.

METHODS

A 3T Siemens clinical scanner was used. Informed consent was obtained from the patient before scanning. The HDMD-SelMQC-CSI sequence has been already described. The sequence encodes Hadamard slices before selective multiple quantum coherence and chemical shift imaging is appended after that. The sequence was approved for human study by the CAMRIS (Center for Advanced Magnetic Resonance Imaging and Spectroscopy) review board. The 5cm 2 channel surface coil was placed over the NHL tumor of a 63 year old male patient having inguinal node lymphoma in the upper thigh. Transmittal pulses were applied using volume coil of the magnet and the surface coil received the signal from the tumor. A multi-slice axial series T2-weighted images were taken for localization of the tumor with the following parameters: FOV 250x250mm, thickness 5mm, TR 2000 ms, TE 13 ms, axial slices. From this the HDMD-SelMQC-CSI sequence was run with the following parameters: FOV 250mm x 250mm, Matrix 10x10 (elliptically sampled), slice thickness 25mm, TR 1500ms, acquisition time 5 min, 2 slice Hadamard encoding (4 pulses). Measurements were taken 2 days before and 2 days after treatment initiation. The patient received ritixmab plus CHOP (cyclophosphamide, doxorubicin, vincristine, prednisone) combination therapy. For normalization of lactate, the Hadamard spin echo water CSI was also acquired. Tumor volumes and PRESS spectra were also measured before and after treatment. The PRESS sequence employed TR=3000 ms, TE=135 ms.

RESULTS

Figure 1A shows a T2-weighted image and Fig 1B shows a HDMD-SelMQC-CSI lactate image before treatment. The lactate image (Fig. 1B) matches with the tumor region in Fig 1A. Table 1 shows tumor volume, Lac:H₂O and tCho:H₂O of the patient 48h before and 48 h after treatment (R-CHOP) initiation. The tumor was quickly responsive to R-CHOP treatment and had volume decrease by 25% at 48 h post treatment. At that time, Lac:H₂O decreased by 70% and tCho:H₂O increased by 15%.

DISCUSSION

The result indicates that changes in lactate of tumor can be detected following treatment in a clinical scanner and suggests that Lac:H₂O is a very sensitive indicator of treatment response to R-CHOP combination therapy in non-Hodgkin's lymphoma patients and precedes tumor volume response. tCho:H₂O was not very sensitive at this early time after treatment. Accural and measurements on more patients are now under progress. We're also comparing this lactate detection method with the wavelet transform method [4] that can derive lactate from a single voxel PRESS spectrum using postprocessing.

Fig.1

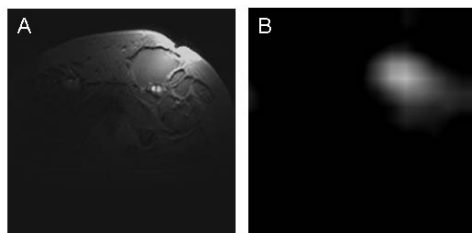


Table 1

	48h before treatment	48h after treatment	Relative changes
Tumor volume	351 cm ³	261 cm ³	25 % ↓
Lac:H ₂ O	2.7e-4	0.8e-4	70 % ↓
tCho:H ₂ O	9.5e-4	10.9e-4	15 % ↑

REFERENCES 1. Lee et al. NMR Biomed 21(2008):723 2. Lee et al. NMR Biomed, DOI:10.1002/nbm.1316 3. Mellon et al. ISMRM 2008 #1577. 4. Serrai et al. MRM 43(2000):649.