

Dynamic contrast-enhanced MRI of cervical tumors during chemo-radiation correlated to tumor regression

U. A. van der Heide¹, C. Arteaga de Castro¹, G. Groenendaal¹, C. A. van den Berg¹, I. M. Jurgenliemk-Schulz¹, and J. M. Roesink¹

¹Radiotherapy, UMC Utrecht, Utrecht, Netherlands

Introduction

In the first weeks of external-beam radiotherapy of patients with cervical cancer, a substantial regression of the tumor volume can be achieved, which benefits the effectiveness of intracavitary boosting in the later phase of the treatment. Weekly MRI exams during treatment were used to monitor this regression. The rate of tumor regression varies between patients, but can be as large as 65% of the volume per week. We investigated if dynamic contrast-enhanced (DCE) MRI prior to, and early in the treatment can be used to predict this regression. Three dimensional mapping of tracer kinetics parameters was used to study the heterogeneity inside tumors and characterize changes during therapy.

Methods

25 patients with cervical cancer were monitored with MRI scans prior to and weekly in the first four weeks of chemo-radiation. T2-weighted sagittal and axial scans were made on a 1.5T MRI scanner. Also, a dynamic contrast-enhanced series was made in each exam: 15 ml of 0.5M gadolinium-DTPA was injected in 10 seconds, followed by a saline flush; Scans were repeated 120 times at a 2.4 second interval with a 3D spoiled gradient echo sequence (TR/TE 4.9/1.6 ms, flip angle 30°, 10 slices, field of view 24x24 cm, reconstruction matrix 256x256x10). The pre-contrast T1 was derived using three pre-scans with different flip angles (4.5, 8 and 16°).

The arterial input function (AIF) was determined by monitoring the signal enhancement in a central region of the femoral artery. Concentration-time curves were analyzed for each voxel using the Tofts model, yielding quantitative 3D maps of the transfer constant K^{trans} and the extravascular extracellular space (EES) fractional volume V_e .

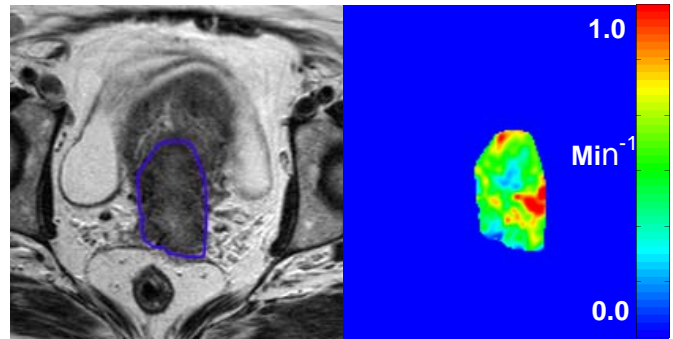


Figure 1: left: T2-weighted MRI of a cervix tumor (blue line) pre-treatment. right: K^{trans} map of the tumor, showing substantial heterogeneity in tissue perfusion.

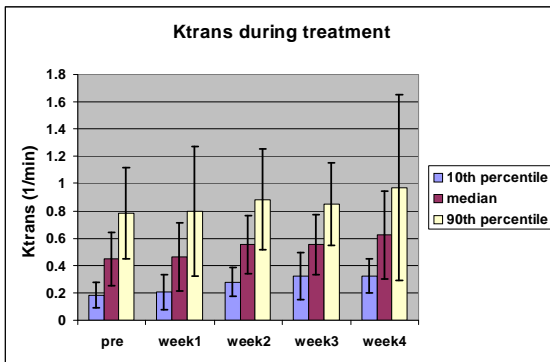


Figure 2: The average value of K^{trans} in the tumor of all 25 patients during treatment. The 10th percentile represents the value of the poorest perfused part of the tumor, the 90th percentile the best perfused part.

Results and Discussion

The average pre-treatment tumor volume was 56 ml (range 5 – 595 ml). Tumors regressed exponentially during the first 4 weeks of treatment at an average rate of 37% per week (range 12 – 65% per week). No correlation was found between the initial tumor volume and the regression rate (Figure 3a).

The perfusion of the tumor, as represented by K^{trans} was very inhomogeneous throughout the tumor (Figure 1). Therefore, we determined the 10th percentile K^{trans} , representing the poorest perfused part of the tumor. Also the median and 90th percentile K^{trans} were determined. For all percentiles a significant increase was found during the course of the treatment (Figure 2). This suggests that a reperfusion of the tumor occurs in the first weeks of the treatment. The 10th percentile K^{trans} seems indicative of the rate of regression. When this value is higher, the regression rate tends to be larger (Figure 3b). However, the correlation is weakened by the existence of some tumors that are extremely inhomogeneous.

Conclusions

The tumor regression rate in the first four weeks of chemo-radiation shows an increasing trend with the K^{trans} in the poorest perfused part of the tumor prior to treatment. This may help optimize the timing and balance of the external-beam radiotherapy and the intracavitary boost.

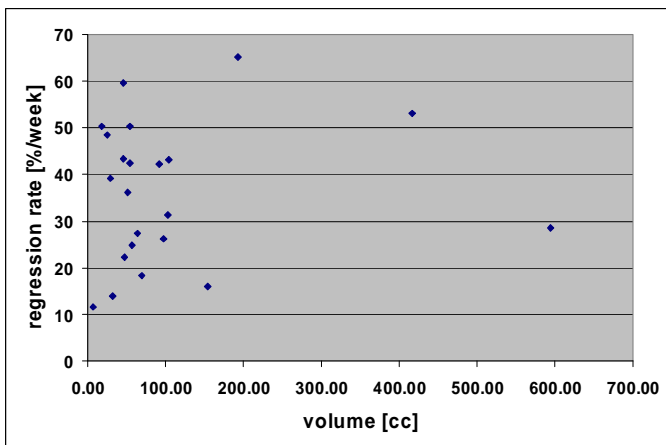


Figure 3a: The regression rate plotted against the pre-treatment tumor volume

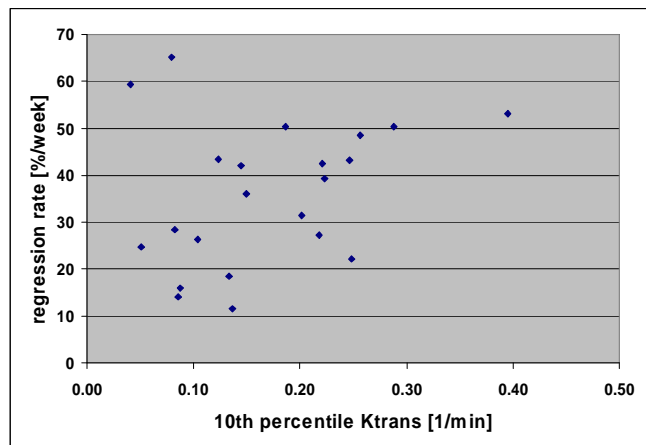


Figure 3b: The regression rate plotted against the value The 10th percentile value of K^{trans} in the tumor.