

## Clinicopathological Correlation of Residual Breast Cancer Diagnosed by MRI in Patients Receiving Neoadjuvant Chemotherapy with and without Bevacizumab (Avastin®)

S. Bahri<sup>1</sup>, J-H. Chen<sup>1,2</sup>, K. Nie<sup>1</sup>, R. S. Mehta<sup>3</sup>, P. M. Carpenter<sup>4</sup>, S-Y. Kwon<sup>4</sup>, H. J. Yu<sup>1</sup>, O. Nalcioglu<sup>1</sup>, and M-Y. Su<sup>1</sup>

<sup>1</sup>Tu & Yuen Center for Functional Onco-Imaging, University of California, Irvine, CA, United States, <sup>2</sup>Department of Radiology, China Medical University Hospital, Taichung, Taiwan, <sup>3</sup>Department of Medicine, University of California, Irvine, United States, <sup>4</sup>Department of Pathology, University of California, Irvine, United States

### Purpose:

Angiogenesis is an essential process to support development and growth of tumors. The vascular endothelial growth factor (VEGF) has been identified as one of the important stimulating mediators. Bevacizumab (Avastin®) is a humanized monoclonal antibody against VEGF developed for anti-angiogenic therapy. Clinical efficacy of bevacizumab for treating colorectal cancer, lung cancer, metastatic breast, and other solid tumors has been investigated. It was first approved for treatment of colon cancer by the Food and Drug Administration (FDA) in 2004, and then approved for lung cancer in 2006. Based on the result that bevacizumab plus paclitaxel has significantly prolonged progression-free survival as compared to paclitaxel alone [1], in February 2008 the FDA granted accelerated approval for bevacizumab to be used in combination with paclitaxel for the treatment of patients with metastatic HER-2 negative breast cancer. Since the treatment effect of bevacizumab is through inhibiting angiogenic vessels, whether the damaged vessels would affect the delivery of MR contrast agents thus leading to under-estimation of residual disease warrants investigation. The purpose of the present work was to study the impact of bevacizumab on the accuracy of MRI in diagnosing residual disease after NAC. The pathological response and the diagnostic accuracy of MRI between patients receiving NAC regimen with and without containing bevacizumab were compared.

### Methods:

From 2004 to 2007, a total of 16 patients (17 lesions, age 46±12) received the NAC treatment protocol with Avastin, and 20 patients (age 47 ±9) received the same treatment protocol without addition of Avastin. All patients had received serial MRI monitoring studies before, during, and after the NAC, and then received definitive surgery. Subtraction images and maximum intensity projection (MIP) images were used for interpretation of residual disease. To ensure consistency in evaluation of the lesion extent, the pre- and post-NAC size measurements for each patient were performed in one review session. The longest dimension of the lesion based on the RECIST criteria was measured. When there was no residual enhancement, or the residual enhancement was equal or lower compared to the normal glandular tissue enhancements elsewhere, the case was determined as a clinical complete responder, with residual lesion size=0. Based on the morphological description of the tumor defined in BI-RADS (Breast Imaging-Reporting and Data System) breast MRI lexicon, the pre-treatment lesions were classified into the mass lesions; or the non-mass lesions (NML) that show diffuse contrast enhancements on MRI without clear tumor boarders. A careful pathological examination was performed to classify the type and the extent of residual disease into 3 patterns: 1) pCR-pathologic complete response, i.e. no residual invasive cancer; 2) Nodular pattern- with confined cancer nodules; and 3) Scattered cell pattern- with small cancer nodules and scattered cancer cells/clusters distributed in a large fibrotic region.

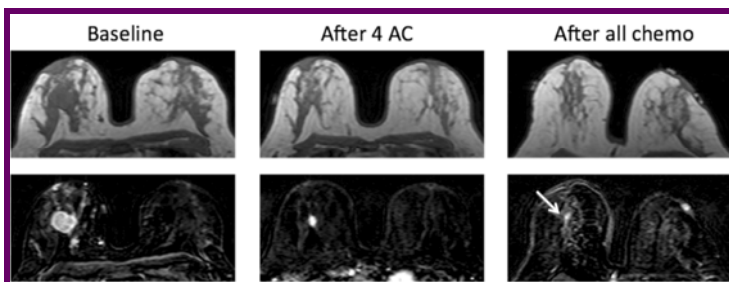
### Results:

Of the 17 lesions receiving Avastin, 5 lesions were pCR (5/17, 29%), 5 lesions showed scattered cell residual disease pattern (5/17, 29%), and 7 lesions shrank down to nodules. Of the 20 lesions without receiving Avastin, 8 lesions were pCR (8/20, 40%), 4 lesions showed scattered cell residual disease pattern (4/20, 20%), and 8 lesions shrank down to nodules. The rates of different pathological response patterns between the two groups were comparable.

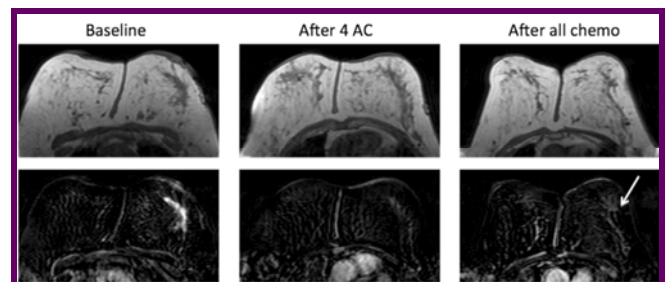
The diagnostic performance of MRI is determined as “true positive”, “true negative”, “false positive”, and “false negative”, as listed in Table 1. In the Avastin group, the overall accuracy was 13/17 (76%). Among 7 lesions that were diagnosed as complete clinical response (no residual disease on MRI), 4 were correct as pCR with the pCR prediction accuracy of 4/7 (57%). In the other group without Avastin, the overall accuracy was 14/20 (70%). Twelve lesions were diagnosed as complete clinical response, and 7 were pCR, with the pCR prediction accuracy of 7/12 (58%). The results between 2 groups were comparable. For lesions that were presented as mass before NAC and shrank down to nodules, the residual size measured on MRI and pathology were very close, with size discrepancy 0.1-0.7 cm for Avastin group, and 0-0.5 cm for no-Avastin group. However, for non-mass lesions, the size discrepancy was much higher, > 5 cm for several cases. Figure 1 illustrates one true positive case showing a mass shrinking down to nodule, and Figure 2 illustrates one false negative case showing a NML lesion that was miss-diagnosed by MRI.

**Table 1. The diagnostic performance of MRI in Avastin and no-Avastin groups, and in a control group with HER2 + cancer receiving Herceptin**

Regimen	pCR Rate	TN	FN	TP	FP	pCR Accuracy	Overall Accuracy
Avastin (N=17)	5 (29%)	4	3	9	1	13/17 (76%)	13/17 (76%)
No-Avastin (N=20)	8 (40%)	7	5	7	1	14/20 (70%)	14/20 (70%)
Herceptin (N=24)	18 (75%)	18	1	5	0	18/19 (95%)	23/24 (96%)



**Figure 1. A mass lesion shrank from 3.4 to 0.8 cm. The pathologic size was 0.2 cm.**



**Figure 2. A 7.6 cm lobular cancer was determined as complete response, but pathology shows scattered cells in 8 cm region.**

### Discussion:

Our results indicate that the pCR rates and residual disease patterns (nodular pattern, and scattered cell pattern-with cells/clusters within a large fibrotic region) were comparable between patients receiving Avastin vs. those without Avastin. The overall diagnostic accuracy of MRI and the accuracy for predicting pCR were comparable between two groups. The use of Avastin did not compromise the diagnostic accuracy. In mass lesions where the tumor boundary is clear and when the tumor shows concentric shrinkage to nodular pattern, MRI is highly accurate in diagnosis of residual disease. However, when the residual cancer cells are presented as small foci or scattered cells/clusters, MRI may not detect them. This problem is due to the intrinsic limitations of MRI, not specific to patients receiving Avastin. For HER-2 positive patients receiving trastuzumab (Herceptin), the pCR rate was much higher, and as the result of great response it is less likely to present residual disease as the scattered cell pattern; as such, the diagnostic accuracy was also much higher. The problem of MRI in detecting small cancer foci or scattered cells and clusters after NAC should be considered when planning for breast conservation surgery after NAC.

[1] Miller K, Wang M, Gralow J, et al. Paclitaxel plus bevacizumab versus paclitaxel alone for metastatic breast cancer. N Engl J Med. 2007; 357(26):2666-2676.