

Ductal Carcinoma in Situ Diagnosed with Contrast-Enhanced Breast MR Imaging. Can Invasion Be Predicted?

M. Goto¹, S. Yuen¹, K. Yamada¹, E. Konishi², and T. Nishimura¹

¹Radiology, Kyoto Prefectural University of Medicine, Kyoto, Kyoto, Japan, ²Pathology, Kyoto Prefectural University of Medicine

Background and Purpose

Preoperative needle biopsy is a standard procedure performed prior to surgery, but it has an inherent limitation, as it is able to observe only part of the entire tumor. This becomes especially problematic in diagnosing ductal carcinoma in situ (DCIS) as there may be areas with invasions at regions that did not undergo biopsy. MR imaging may thus play an important role in providing a bird's eye observation of the entire mass. The purpose of this study was to retrospectively assess the MR imaging features that can be used to predict interstitial tumor invasion in lesions diagnosed as DCIS on biopsy.

Materials and Methods

From November 2004 to January 2007, DCIS without invasion was diagnosed by means of needle biopsy in 47 patients. We retrospectively assessed the following MR imaging findings of these cases: lesion size, lesion type (mass or non-masslike), kinetic curve of contrast enhanced MR studies, and internal features (distribution modifiers, clustered ring enhancement, internal distortion and internal nodular lesion on contrast-enhanced and/or T2-weighted imaging) on non-masslike enhancement lesion. Each MR imaging feature was compared between cases with and without invasion.

Results

Over half of the cases (n = 27, 57%) were found to have invasive disease after surgery. The majority of these lesions (45 of 47, 96%) were classified as non-masslike enhancement lesions, and two were classified as mass lesions. Two mass lesions were determined to be invasive cancer (100%). Eight of the 45 (18%) non-masslike lesions showed internal nodular lesion on contrast-enhanced and/or T2-weighted MR image, and they were all determined to be invasive cancer (Fig.1). Statistically significant differences were found for this finding between DCIS and invasive cancer (p=0.012, 0.027). All other MR imaging features, on the other hand, did not show significant differences. Finally, ten of the 27 (37%) invasive cancers could be diagnosed using the MR imaging findings listed above (Fig.2). Among these 10 cases, nine (90%) lesions had ≥ 1 cm histological invasive nest.

Conclusion

MR imaging features were shown to be useful in diagnosing occult invasion of biopsy-proven DCIS. It appeared possible to detect a ≥ 1 cm histological invasive nest using MR imaging, and thus it is considered helpful in making appropriate decision for the location of needle biopsy. On the other hand, it is possible that a ≤ 1 cm invasive nest cannot be depicted, even with relatively advanced MR imaging techniques.

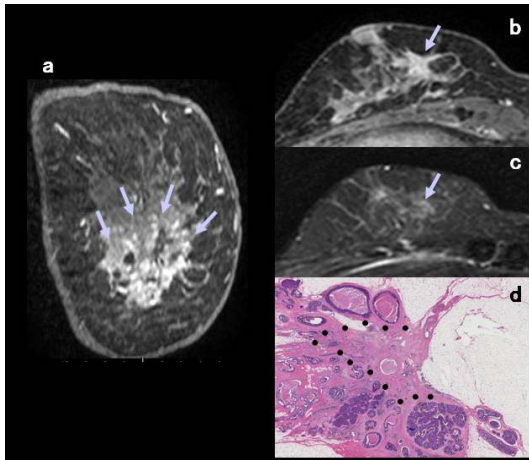


Fig. 1a-d A 62-year-old woman with invasive ductal carcinoma with surrounding DCIS in the right breast. **a** Coronal multiplanar reconstruction of contrast-enhanced T1-weighted MR image shows non-masslike, segmental enhancement (arrows). **b** Axial contrast-enhanced image

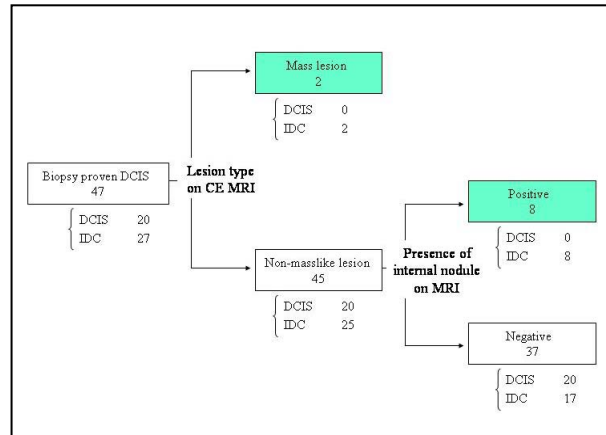


Fig. 2 Interpretation model of differentiation between DCIS and invasive cancer. Terminal nodes of invasive cancer are shaded.