

Diffusion MR Imaging: ADC Mapping of Malignant and Benign Breast Tumors

S. B. Thakur^{1,2}, N. Ishill³, D. D. Dershaw², J. A. Koutcher^{1,2}, and E. A. Morris²

¹Medical Physics, Memorial Sloan Kettering Cancer Center, New York, NY, United States, ²Radiology, Memorial Sloan Kettering Cancer Center, New York, NY, United States, ³Epidemiology-Biostatistics, Memorial Sloan Kettering Cancer Center, New York, NY, United States

Introduction

Diffusion MRI is a noninvasive technique which provides information about early changes in morphology and physiology of tissues by monitoring changes in the local apparent diffusion coefficient (ADC) of water molecules. These changes in ADC values are associated with different degrees of restriction to motion and are connected with pathological modifications such as those encountered in tumors. In recent years, diffusion imaging has demonstrated potential in discriminating malignant from benign breast tumors (1, 2) and in assessing progression of disease following therapy (3).

In this work we present the first phase of an ongoing investigation aimed at establishing the clinical usefulness of diffusion weighted imaging (DWI) and apparent diffusion coefficients (ADCs). Diffusion MRI examinations were performed on patients who had positive MRI findings and underwent MRI-guided interventional procedures. Our objective was to determine if the addition of a diffusion examination is practical in a clinical setting and if the acquisition of quantitative ADC values can improve the detection efficiency of breast malignancy. Histopathology examination was used as the reference standard to discriminate conclusively between malignant and non lesions.

Methods

The IRB approved the HIPAA-compliant retrospective study and issued a waiver of informed consent. The diffusion data were collected from 17 patients during their clinically scheduled MRI-guided preoperative needle localization or biopsy procedures before injection of contrast agent.

The diagnostic breast MRI protocol includes multi-slice FSE T₂-weighted MRI with fat saturation, pre-contrast 3D SPGR T₁-weighted MRI with and without fat saturation, DWI with fat-saturation, and DCE MRI (3D SPGR) with fat saturation. The reading of MRI was based on morphology of contrast enhanced lesion and contrast wash-out kinetics (4). In addition, DWI images were obtained by using single-shot spin-echo EPI sequence with a pair of gradient pulses in all three orthogonal axes. The parameters were TR=6000 ms, TE=100 ms, FOV=26 cm, slice thickness is 4 mm with 0 mm spacing and matrix size of 192x128. The orientation and location of these images were prescribed similar to the sagittal T₁-weighted images for unilateral and axial T₁-weighted images for bilateral breast cases. The gradient *b* values were 0 and 1000 sec/mm². With 4 to 6 averages, and the duration of the DWI examination was about 1.5 minutes.

All studies were conducted with 1.5T GE Excite systems with the body coil as the transmitter and a sentinel coil or phase arrayed coil as the receiver. Seventeen subjects (5 malignant and 12 benign) were evaluated. The lesion pathology was determined from a histological examination performed on biopsy or needle localization samples obtained after the MR scan.

ADC maps were calculated with GE's FUNCTOOL software. With the use of T₁-weighted post contrast image, regions of interest (ROIs) were manually drawn surrounding the enhancing lesions or normal tissue. These ROIs were then applied to sagittal/axial diffusion images data by comparing to post contrast data. Quantitative ADC measures between malignant lesions, benign lesions and normal breast tissue were compared (Table.1).

Results and Discussions

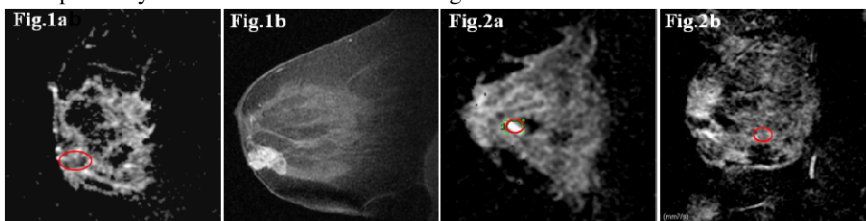
Fig. 1a and 1b shows the ADC parametric map and the matching post-contrast T₁-weighted MR image for a women with invasive ductal carcinoma that was confirmed with biopsy procedure. By drawing a region of interest (green circles on image) corresponding to enhanced lesion from post contrast images, we calculated the diffusion coefficient to be 0.0011±0.0003 mm²/s (Mean±SD). SD represents the standard deviation. Fig. 2a and 2b show the ADC maps of benign cystic and fibroadenoma lesions. Lesions are indicated by green circles. ADC coefficients were calculated as 0.0012±0.0003 mm²/s for fibroadenoma lesion similar to malignant lesions and 0.0020±0.0002 mm²/s for benign cystic lesion as reported in literature (3). The pathology results showed that 5 of the 17 lesions were malignant and the other 12 were benign. Table 1 lists the average mean and standard deviations of diffusion coefficients calculated from group of benign and malignant lesions. Our calculated mean ADC coefficients were in the range of values that have been previously reported for benign and malignant lesions (1, 2).

Group	Average(Mean)	Average(SD)
Benign (n=12)	0.00183	0.00042
Malignant (n=5)	0.00134	0.00032

The ADC values show that malignant tumors have a lower value than benign lesions. These findings are consistent with similar work on breast tumors and reflect the increased cellular density. The fibroadenoma lesions have ADC value close to malignant tumors similar to the reported values (3).

Conclusion

Our preliminary study confirms the usefulness of diffusion studies for breast cancer diagnosis. ADC values of confirmed malignant lesions were much lower than those of benign lesions. Since ADC values are roughly proportional to cellular density (High density Low ADC, Low density High ADC) they represent a valuable biomarker for detecting malignant lesions (which are believed to have a higher cellular density). Although this study was conducted on a limited patient population, the findings suggest that cell density might play an important role in the different ADCs obtained from benign and malignant breast lesions and the measurement of extracellular water content may be an additional feature that can improve MRI specificity and understand treatment changes.



References 1) Guo, Y. JMIR 16, 172(2002). 2) Woodhams, R et al., Magn Reson Med. Sci. 4, 35 (2005). 3) Kuroki, Y et al., Breast Cancer 15, 212 (2008). 4) Liberman, L. et al., AJR 179, 171 (2002).

