

High-resolution Contrast-enhanced MR Angiography for the Assessment of Vascular Complications of Pancreas Transplantation: 1.5 T versus 3T

A. M. Housseini^{1,2}, P. T. Norton¹, I. M. Maged^{1,2}, E. A. Abdel-Gawad^{1,3}, T. M. Schmitt⁴, K. L. Brayman⁴, H. Bonatti⁴, T. L. Pruett⁴, T. E. Huerta¹, and K. D. Hagspiel¹

¹Department of Radiology, University of Virginia Health System, Charlottesville, VA, United States, ²Department of Radiology, Suez Canal University, Ismailia, Ismailia, Egypt, ³Department of Radiology, El Minya University, El Minya, El Minya, Egypt, ⁴Department of Surgery, University of Virginia Health System, Charlottesville, VA, United States

Introduction:

Pancreatic transplantation (PT) is a definitive treatment for patients with type 1 diabetes mellitus. The incidence of vascular complications after PT is 30% and considered the most common cause of early transplant failure. Clinical indicators of rejection are insensitive and nonspecific. Similarly, CT and US are unreliable for detection of acute rejection. High-resolution dynamic contrast enhanced 3D MR angiography (3D CEMRA) at 1.5T is being used in several centers to monitor pancreas allografts with good accuracy (1-6). MRA at 3T is considered superior to 1.5T due to increases in signal to noise and spatial resolution, although for most vascular territories proof is still lacking. The purpose of this study is to compare the performance of 3D CEMRA at 1.5T and 3T in the assessment of the normal anatomy and vascular complications of pancreas allografts.

Methods:

Retrospective review of all 3D CEMRA studies in patients enrolled in the graft surveillance program at our institution. All MR studies were performed on high performance whole body systems. All 3T MR studies were performed on a whole body MRI system (Trio, Siemens Medical Systems, Malvern, PA) using a 6 channel body matrix coil. A sequential 3D FLASH sequence was used with an excitation flip angle of 23°. Sequence parameters: matrix size 384x384; TR/TE 2.92/1.18 ms; FOV 400 mm; receiver bandwidth 590 Hz/pixel, parallel imaging (GRAPPA) acceleration factor 3. A minimum of two image acquisitions were performed in order to acquire arterial and venous phase images. Acquisition time for one dataset was 20 seconds and the spatial resolution was 1.0 x 1.0 x 1.2 mm uninterpolated. 1.5T MR studies were performed on a whole body MRI system (Avanto, Siemens Medical Systems, Malvern, PA). A sequential 3D FLASH sequence was used with an excitation flip angle of 15°. Sequence parameters: matrix size 384x448; TR/TE 2.61/1.09 ms; FOV 390 mm; receiver bandwidth 700 Hz/pixel, parallel imaging (GRAPPA) acceleration factor 2. A minimum of two image acquisitions were performed in order to acquire arterial and venous phase images. Acquisition time for one dataset was 31 seconds and the spatial resolution was 0.8 x 1.5 x 1.5-1.9 mm uninterpolated. 20ml gadobenate dimeglumine (Multihance; Bracco Imaging, Milan, Italy) were injected at 2.0 ml/sec with a power injector. Injection delay was calculated for peak arterial enhancement during the acquisition of the central lines of k-space for the first acquisition. Overall image quality, contrast bolus timing and the presence of artifacts were assessed qualitatively on a four point Likert scale. (Image Quality: 1 = excellent = interpretability sufficient for treatment planning, 2 = good = minor impairments in image quality fully sufficient for treatment plan, 3 = poor = some impairment of image quality, but sufficient for treatment planning and diagnostic, 4 = non-diagnostic = not sufficient for treatment planning; Bolus Timing: 1 = excellent = pure arterial phase enhancement without venous contamination allowing delineation of all relevant arterial structures, 2 = good predominant arterial enhancement with minimal venous contamination allowing identification of all arterial structures, 3 = fair predominant arterial enhancement with significant contamination allowing identification of all major arterial structures but not side branches, 4 = poor = poor arterial enhancement and/or severe venous contamination resulting in non-diagnostic study; presence of artifacts: 1 = absent, 2 = present, not affecting image interpretation, 3 = present, affecting image interpretation, 4 = severe, rendering study nondiagnostic). Pancreatic parenchymal enhancement was assessed according to qualitative criteria proposed by Krebs et al (4): 1 = homogeneous and normal enhancement, 2 = inhomogeneous enhancement, 3 = decreased enhancement and 4 = absent enhancement. Angiographic correlation was available for 7 MRA's. For the patients with DSA correlation visibility and patency of the lumen of the arteries supplying the transplants and their respective anastomoses were assessed on a workstation in a semiquantitative fashion on a graded scale. (1 = completely visualized and patent, 2 = completely visualized and 50% or less stenosis or filling defect, 3 = completely visualized and more than 50% stenosis or filling defect, 4 = completely visualized and complete occlusion, 5 = not visualized). The following vascular segments were assessed: recipient: distal aorta, common, external and internal iliac arteries; transplant: iliac Y-graft (where applicable), splenic limb and superior mesenteric limb as well as the respective anastomoses.

Results:

25 1.5T 3D CEMRAs in 12 patients and 25 3T 3D CEMRA's in 15 patients were available for review. All 50 CEMRAs were technically successful and considered diagnostic. Only six studies were considered completely normal, in 44 exams vascular complications or signs suggestive of rejection were detected. Complications detected included complete or partial arterial graft occlusion, stenoses of the arterial graft and graft anastomoses, venous thromboses, arteriovenous fistulae and pseudoaneurysm formation. For the patients with angiographic correlation overall agreement with MRI was excellent and did not differ between 1.5 T and 3T. Image quality for 1.5T and 3T was 1.43 (SD 0.57) and 1.41 (SD 0.57). Contrast bolus timing for 1.5T and 3T was 1.29 (SD 0.53) and 1.52 (SD 0.53) and presence of artifacts for 1.5T and 3T was 1.79 (SD 0.63) and 1.66 (SD 0.63). There were no statistically significant differences between 1.5T and 3T.

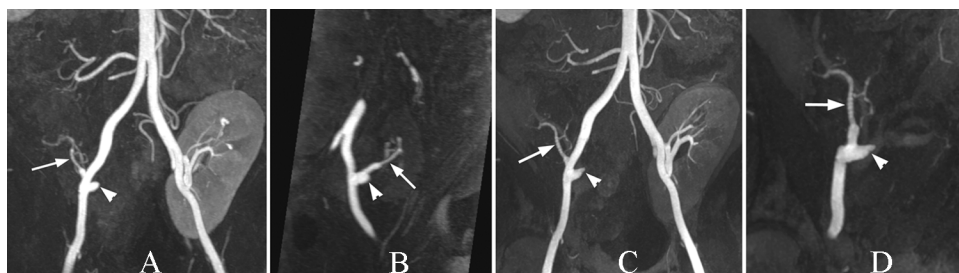


Figure: 46 year old male patient after combined pancreas kidney transplant using the Systemic Bladder Drainage (SBD) Technique. Full volume MIP and oblique subvolume MIP at 1.5T (A,B) and 3T (C,D) images show patent Y-graft and splenic limb of allograft (arrow) as well as occluded superior mesenteric limb of the allograft (arrowhead). (MIP=Maximum Intensity Projection)

Conclusion:

Both 1.5T and 3T CEMRA of pancreas allografts are suitable for the assessment of arterial and venous vascular anatomy of pancreas allografts. Despite gains in spatial resolution and signal to noise on the 3T systems, this did not lead to increased accuracy in our experience.

References:

1. Grewal HP, et al. Transplantation 1993; 56: 609-612.
2. Edelman RR, et al. Invest Radiol 2006; 41(2): 175-180.
3. Hagspiel KD, et al. Radiology 2007; 242: 590-599.
4. Krebs TL, et al. Radiology 1999; 210(2): 437-442.
5. Dobos N, et al. Radiographics 2005; 25(3): 687-695.
6. Pozniak MA, et al. Radiol Clin North Am 1995; 33(3): 581-594.