

Magnetic Resonance Cholangio-Pancreatography (MRCP) of post-transplant ischaemic-type biliary lesion ITBL: which is the best imaging sequence?

A. Helck¹, C. J. Zech¹, H. Diepolder², W. Sommer¹, M. F. Reiser¹, C. Glaser¹, and K. A. Herrmann¹

¹Departement for Clinical Radiology, University of Munich/Campus Grosshadern, Munich, Bavaria, Germany, ²Departement for Internal Medicine II, University of Munich, Munich, Bavaria, Germany

Purpose:

Orthotopic liver transplantation has become increasingly common and is a well accepted treatment of end-stage liver disease (Starzl et al.). Beside graft rejection, biliary complications are the most common reason for liver dysfunction in patients after OLT (Oliver et al.). Ischaemic-type biliary lesion (ITBL) is a distinct type of complication which most often is represented by nonanastomotic strictures with upstream dilatation and/or intraductal cast formation (Sanchez-Urdazpal et al.). ITBL is a serious complication with potentially disastrous outcome, sometimes requiring re-transplantation. Therefore, distinguishing ITBL from other types of post-transplant biliary strictures is crucial. Magnetic-Resonance-Cholangio-Pancreatography (MRCP) is well established as a non-invasive imaging modality for the post-transplant investigation of the biliary system (Boraschi et al., Fulcher et al.). MRCP-sequences are based on strongly T2-weighted imaging in order to depict the fluid-filled biliary and pancreatic duct system, most commonly used are RARE, HASTE and 3D-TSE (Figure 1). The value of each particular sequences in the diagnosis of ITBL is less clear. The purpose of this study was to determine the best imaging sequence used in MRCP to establish the diagnosis of ITBL.

Materials and Methods:

Twenty patients with signs and laboratory findings of biliary obstruction after liver transplantation were retrospectively included in the study. All patients had undergone MRCP in a 1.5T multi-channel MR-scanner. The standard imaging protocol included high resolution T2w 3D-TSE, T2w SSFSE with fat saturation and RARE imaging. Two independent board-certified radiologists experienced in liver MRI evaluated the presence and signs indicative of ITBL for each of these sequences, separately. These signs included the presence and character of non-anastomotic stricture, cholestasis and intraluminal biliary cast (Figure 2). ROC analysis was performed to determine the inter-observer variation and diagnostic value for each sequence. ERCP was used as standard of reference. Kappa-statistics was applied to evaluate inter-observer agreement.

Results:

Values for the area under the curve (AUC) were 0.91 and 0.98 for 3D-TSE, 0.79 and 0.82 for SSFSE and 0.60 for RARE sequences, respectively (Figure 3). Differences were statistically significant between AUC of RARE and TSE sequences ($p=0.003$) but not for SSFSE and TSE. SSFSE was superior to TSE in determining the character of a stricture (Figure 3), TSE was superior in the detection of intra-luminal biliary cast. Kappa values for inter-observer agreement were $\kappa=0.54$ for SSFSE and $\kappa=0.69$ for TSE.

Conclusion:

High resolution 3D-TSE yields best results in detecting and correctly diagnosing ITBL in liver transplant patients with statistic better results than RARE-sequences. SSFSE is also highly effective in classifying the type of the stricture.

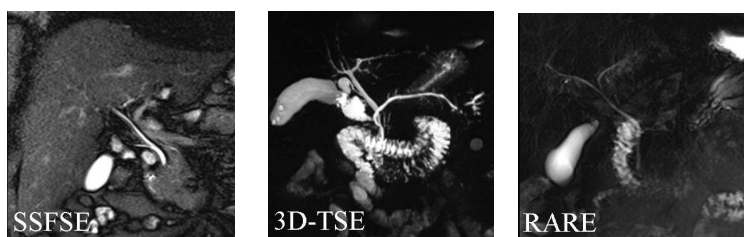

Figure 1: Most commonly used MRCP-sequences (without pathology)

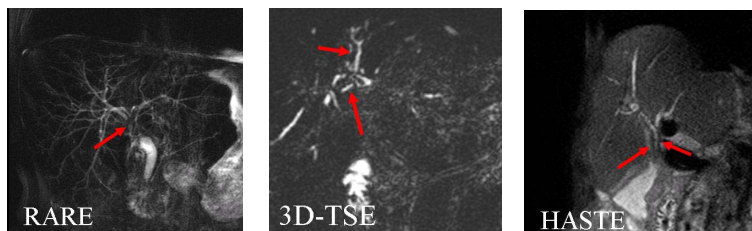


Figure 2: Example of ITBL criteria: Extrahepatic non anastomotic stricture (left), intraductal filling defects (middle), biliary wall thickening (right)

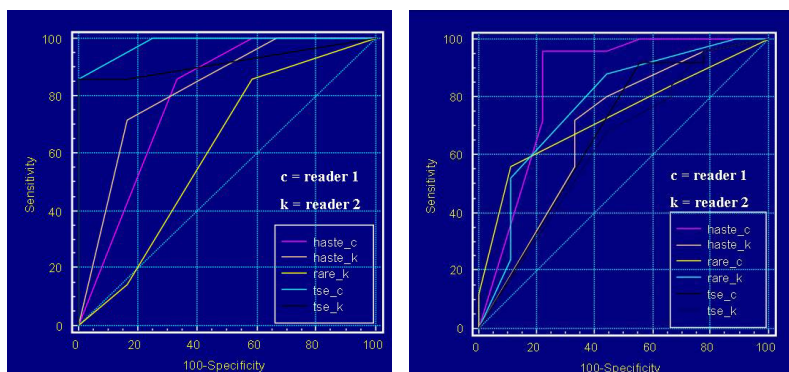


Figure 3: Results for stenosis (left) and results for ITBL/biliary cast (right)

References:

- Boraschi P, Braccini G, Gigoni R, Sartoni G, Neri E, Filippini F, Mosce F, Bartolozzi C. Detection of biliary complications after orthotopic liver transplantation with MR cholangiography. *Mag Res Imaging* 2001;19:1097-1105
- Fulcher AS, Turner MA, Orthotopic liver transplantation: Evaluation with MR cholangiography. *Radiology* 1999;211:715-722
- Oliver JH, Federle MP, Campbell WLk, Zajko A. Imaging the hepatic transplant. *Radiol Clin Norht Am* 1991;29:1285-1298
- Sanchez-Urdazpal L, Sterioff S, Janes C, Schwerman L, Rosen C, Krom RA. Increased bile duct complications in ABO incompatible liver transplant recipients. *Transplant Proc* 1991;23:1440-1
- Sanchez-Urdazpal L, Gores GJ, Ward EM, Maus TP, Wahlstrom HE, Moore SB, et al. Ischemic-type biliary complications after orthotopic liver transplantation. *Hepatology* 1992;16:49-53
- Starzl TE, Marchioro TL, Vonkaulla KN, Hermann G, Brittain RS, Waddell WR. Homotransplantation of the liver in humans. *Surg Gynecol Obstet* 1963;117:659-76