

Characterization of the effects of different classes of anesthesia on gut motility in the rat small intestine using dynamic MRI

A. Ailiani¹, T. Neuberger², G. Banco³, J. Brasseur³, N. Smith¹, and A. Webb⁴

¹Bioengineering, Penn State University, University Park, PA, United States, ²Huck Institute, Penn State University, United States, ³Mechanical Engineering, Penn State University, ⁴Radiology, Leiden University Medical Center, Leiden, Netherlands

Introduction. Macro scale gut motility is often described in the literature by two dominant motions, peristalsis and segmental. Peristalsis and segmental motions are activated in the jejunum of the small intestine during transport and mixing of the food chyme, respectively. Isoflurane and inactin are two of the most commonly used anesthetics in animal experiments, and have indirectly been seen to have different effects on gut motility. For example, the gastrointestinal (GI) transit is reduced by 50% in rats that were exposed briefly to isoflurane [2]. The propulsion activity also did not increase in rats that were previously treated with the prokinetic drug metochlopramide [2]. In contrast, treatment with inactin is reported not to interfere with brainstem autonomic reflexes and produces stable physiological parameters [3]. In post operative procedures performed on rats treated with inactin, normal fed-like motility was observed [4-5]. The aim of this current study is to directly and noninvasively quantify and compare the motility patterns of rats anesthetized with inactin vs. isoflurane.

Materials and Methods. In two different sets of experiments, rats (250-300 g) were anesthetized using either isoflurane/oxygen gas (n =8) or i.p injection of inactin mixed with saline (n=5). The MRI protocol and steps involved in the post processing of the acquired dynamic images to compute spatio-temporal maps were similar to those described in our previous study [1]. Each motility sequence was acquired at an imaging rate of 6 frames per second, registered to filter breathing artifacts, segmented using in-house segmentation software, and finally spatio-temporal maps and frequency analysis were used to quantify and visualize the complex motility patterns.

Results and Discussion. Consistent with data in the literature we found that isoflurane affects the gut motility to a larger extent than inactin. For example, in inactin the inactive state of the gut is relatively short (~ 26 to 40 s) as compared to isoflurane (~ 220 to 440 s), and the speed of propagation (8.34 ± 1.95 mm/s) is two-fold higher than in isoflurane (4.34 ± 0.35 mm/s). Figures 1(a) and 1(b) show spatio-temporal maps corresponding to peristaltic and segmental motilities, respectively, for inactin treated rats. These are interspersed between inactive periods, as shown in Figures 1(c) and 1(d). In contrast, Figure 1(e) shows a much longer period of inactivity for the rats anesthetized with isoflurane.

Conclusion. Dynamic MRI and spatio-temporal analysis showed that the inactive state of the gut was relatively higher in the rats treated with isoflurane than with inactin, and that the speed of propagation and wavelength of peristaltic motility and the frequency and speed of collapse of segmental motility were higher in the rats treated with inactin. These preliminary results show that inactin anaesthesia does not have the same inhibitory effects on the gut motility as isoflurane, confirming and extending previous observations to this effect.

References. (1) Ailiani, A., et al., Proc. Intl. Soc. Mag. Reson. Med. 15, 2007: p. 626. (2) Torjman, M.C., et al., Int J Pharm, 2005. 294(1-2): p. 65-71. (3) Buelkesam, J., et al., Lab Anim Sci, 1978. 28(2): p. 157-162. (4) Sababi, M., et al., Acta Physiol Scand, 2001. 172(2): p. 115-22. (5) Sababi, M., et al., Acta Physiologica Scandinavica, 1996. 158(1): p. 45-52.

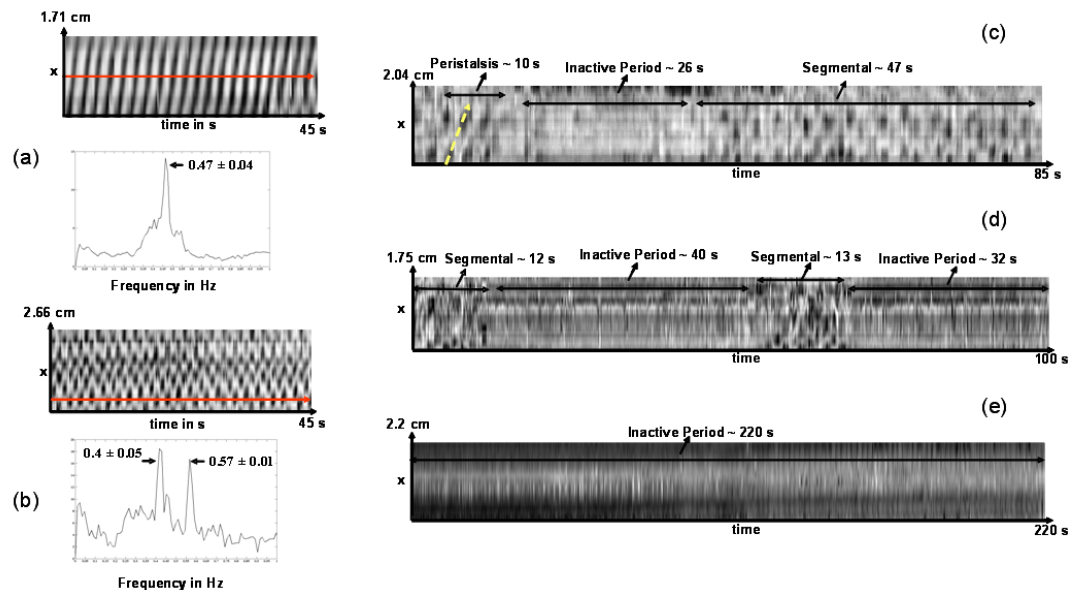


Figure 1: A spatio-temporal map of (a) peristaltic and (b) segmental motility. Frequency analysis of the signals result in a single frequency for peristalsis (a) and two dominant frequencies for segmental (b). (c) and (d) Spatio-temporal maps of the dormant state of the gut in the rats treated with inactin, which is seen between two motility patterns such as peristalsis and segmental or segmental and segmental. (e) The spatio-temporal map of an extended dormant state of the gut in rats anesthetized with isoflurane.