

Intraindividual comparison of gadobenate dimeglumine (MultiHance®) and Ferucarbotran (Resovist®) enhanced MR imaging of hypervascular liver lesions

G. Schneider¹, W. Loytved², L. Grazioli³, R. Semelka⁴, G. Morana⁵, M. A. Kirchin⁶, A. Buecker², and P. Fries²

¹University Hospital of Saarland, Homburg / Saar, Germany, ²University Hospital of Saarland, Germany, ³University of Brescia, Italy, ⁴University of North Carolina at Chapel Hill, United States, ⁵General Hospital Cai Foccello, Treviso, Italy, ⁶Bracco Imaging SpA, Milan, Italy

Purpose: It is generally accepted that MR contrast agents are essential for adequate depiction and characterization of focal liver lesions (FLL) and that liver-specific contrast agents offer significant advantages over conventional non-specific gadolinium-based agents such as gadopentetate dimeglumine (Gd-DTPA, Magnevist) and gadodiamide (Gd-DTPA-BMA, Omniscan). Liver-specific contrast agents fall into two broad categories. On the one hand there are the gadolinium-based dual contrast agents gadobenate dimeglumine (Gd-BOPTA, MultiHance) and gadotexate (Gd-EOB-DTPA, Primovist), which combine the properties of the conventional gadolinium agents with those of agents targeted specifically to hepatocytes, thereby permitting both routine T1w dynamic phase imaging (i.e. image acquisition during the arterial, portalvenous and equilibrium phases) and delayed T1w hepatobiliary phase imaging after contrast agent uptake by functioning hepatocytes, and on the other hand there are the superparamagnetic iron oxide (SPIO)-based agents such ferumoxides (Ferridex, Endorem) and Ferucarbotran (Resovist) which are targeted to the Kupffer cells and are used in conjunction with delayed T2w imaging. In the case of Resovist, the ultrasmall size of the iron oxide particles permits additional T1w dynamic imaging in a manner similar to that of the gadolinium agents. As yet there is still no consensus on the relative values of the two imaging approaches and comparatively few studies have been performed to compare the different types of agent. The present study was therefore performed to intra-individually compare MultiHance and Resovist for enhanced MR imaging of the liver in patients with hypervascular liver lesions.

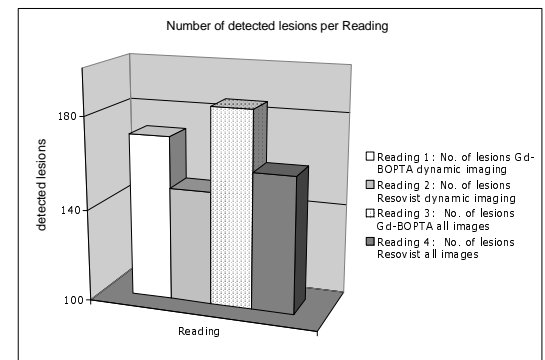
Methods: Forty-three patients with hypervascular liver lesions each underwent two MR imaging examinations. The first study was performed with MultiHance and the second, after an interval of 3 to 7 days, with Resovist. It was necessary to perform MultiHance-enhanced imaging first in order to avoid adverse influences on the MultiHance-enhanced exam caused by the extended residence time of iron oxide particles in the liver. The imaging protocol comprised unenhanced T1w and T2w acquisitions as well as dynamic T1w acquisitions after bolus injection of either MultiHance (0.05 mmol/kg BW) or Resovist (< 60 kg BW 486 mg Ferucarbotran, > 60 kg BW 756 mg Ferucarbotran). Images in the hepatobiliary phase after MultiHance injection were acquired between 45 min and 2 hours post-injection. Delayed images during the Kupffer cell phase after Resovist injection were acquired at 20 min post-injection.

All images were transferred to an external workstation and were prepared for blinded off-site evaluation. Blinded evaluation was performed using a dedicated viewer on CD-rom that automatically displayed images from each patient in a standard fashion. A total of four readings were performed for each patient. The order of patient presentation was randomized for each reading.

- **Reading (1):** unenhanced T1w and T2w images plus dynamic phase images after MultiHance injection.
- **Reading (2):** unenhanced T1w and T2w images plus dynamic phase images after Resovist injection.
- **Reading (3):** unenhanced T1w and T2w images plus dynamic and hepatobiliary phase images after MultiHance injection.
- **Reading (4):** unenhanced T1w and T2w images plus dynamic and Kupffer cell phase images after Resovist injection.

The total number of lesions detected in each image set was determined and the size, location and degree of vascularization of each lesion were recorded for subsequent lesion tracking. Finally a definite diagnosis for each lesion was assigned. Thereafter, Student's t-test was used to compare findings from each reading to investigate the potential value of dynamic plus delayed phase imaging with each contrast agent relative to dynamic phase imaging alone, and also possible differences between MultiHance and Resovist for lesion detection.

Results: A total of 211 lesions were detected on-site. All lesions were biopsy proven or were followed up after 12 months. The final diagnoses were as follows: 3 solitary adenomas, 15 adenomas in patients with liver cell adenomatosis, 76 HCC, 16 NRH, 43 FNH, 5 haemangiomas, 41 cysts, 8 hemangioendotheliomas and 4 metastases. A significant difference was noted between MultiHance and Resovist for the detection of lesions when only dynamic phase images were evaluated (MultiHance: 171/211 lesions detected, Resovist 149/211 lesions detected; $p=0.03$) (Table 1). Likewise, comparison of MultiHance and Resovist for lesion detection when both dynamic and delayed phase images were evaluated revealed a further significant difference (MultiHance: 185/211 lesions detected, Resovist 159/211 lesions detected; $p=0.02$). Finally, the added value of delayed phase imaging was significant for MultiHance (171 vs. 185; $p=0.01$) but not significant for Resovist (149 vs. 159; $p=0.07$). Differences between the two agents were noted particularly for the group of HCC lesions; with MultiHance detection of HCC in a cirrhotic liver was mainly based on dynamic imaging (45 of 53 HCC lesions in patients with liver cirrhosis were detected). Conversely, Resovist enhanced imaging detected only 37 of 53 HCC lesions in cirrhotic liver and 6 false positive lesions were noted in the Kupffer cell phase.



Conclusion: Based on the results of our study, detection of hypervascular FLLs is significantly better with MultiHance than with Resovist. Moreover, whereas delayed hepatobiliary phase imaging with MultiHance permits detection of significantly more lesions than dynamic phase imaging alone, delayed phase imaging with Resovist provides no significant benefit over dynamic imaging alone. A particular benefit of MultiHance is in patients with liver cirrhosis and HCC: MultiHance demonstrated better sensitivity and specificity for lesion detection as compared with Resovist. This was mainly due to greater sensitivity for the detection of hypervascular lesions during dynamic arterial phase imaging.