

# Inhance (Inflow Inversion Recovery) Non-contrast Renal MRA: Comparison with 3D Gadolinium Enhanced MRA in Clinical Patients

J. F. Glockner<sup>1</sup>, N. Takahashi<sup>1</sup>, A. Kawashima<sup>1</sup>, D. Woodrum<sup>1</sup>, D. W. Stanley<sup>2</sup>, N. Takei<sup>3</sup>, M. Miyoshi<sup>3</sup>, and S. Wei<sup>2</sup>

<sup>1</sup>Radiology, Mayo Clinic, Rochester, MN, United States, <sup>2</sup>GE Healthcare, Waukesha, WI, United States, <sup>3</sup>Japan ASL, GE Yokogawa Medical Systems, Hino, Japan

**Purpose:** Contrast-enhanced MR Angiography (CE-MRA) is a widely accepted technique for evaluation of the renal arteries; however, recent concerns regarding the development of nephrogenic systemic fibrosis (NSF) after gadolinium contrast agent administration in patients with reduced renal function have emphasized the need for robust non-contrast MRA methods. One such technique is steady state free precession with in-flow inversion recovery (Inhance). We performed both Inhance MRA and 3D CE MRA in 24 patients referred for renal or abdominal MRA and evaluated Inhance images for accuracy in detection of renal artery stenosis as well as image quality and artifacts.

**Methods:** Inhance is a respiratory-triggered 3D steady state free precession sequence in which high arterial signal intensity is achieved via inflow effect during the inversion time of a slab inversion pulse (IR). The IR pulse suppresses static tissue and inflowing venous blood and is applied to the imaging volume and a variable volume inferior to the imaging slab. An axial volume was acquired with the following parameters: TR/TE 4.0/2.0 msec, TI 200 msec, flip angle 70°, receiver bandwidth 125kHz, FOV 30-42 cm, section thickness 2 mm, 56 views, imaging matrix 256x256, with parallel imaging acceleration factor 2, spectral spatial saturation pulse, and respiratory triggering.

3D CE MRA was performed in a coronal oblique plane with the following parameters: TR/TE 3.4/1.6ms, flip angle 30°, receiver bandwidth 83 kHz, FOV 26-30cm, section thickness 1.6mm, 42 views, matrix 256x224. 0.1 mM/kg gadolinium contrast was injected at 3 ml/s, with the scan delay determined by a test bolus.

24 patients referred for renal or abdominal MRA had both Inhance and 3D CE MRA performed. Inhance images were evaluated independently by two readers who assessed each renal artery for the presence or absence of significant (>50%) stenosis. Two separate readers in consensus graded the CE MRA images in a similar fashion, and also qualitatively assessed visualization of proximal and distal main renal arteries, intrarenal arteries, and accessory arteries in the Inhance and CE MRA sequences using a 5 point scale (1 = uninterpretable, 5 = perfect image).

**Results:** Inhance images were judged interpretable in all cases by one reader and in 23/24 cases by the second reader. CE MRA revealed significant (>50%) stenosis in 11/54 renal arteries. Sensitivity and specificity for detection of significant (>50%) renal artery stenosis for the two readers versus CE MRA are listed in Table 1. Reader 1 detected 52/54 renal arteries; reader 2 did not evaluate 9 accessory renal arteries, which reduced his sensitivity relative to reader 1. Two accessory arteries were not detected by reader 1; these were not included in the Inhance FOV, and one of these had a severe stenosis. Examples of Inhance and conventional CE MRA images in a patient with significant renal artery stenosis are shown in Fig. 1. Fig. 2 shows ratings of image quality for proximal and distal main renal arteries, intrarenal branches, and accessory arteries.

	Sens	Spec
<b>Reader 1</b>	91% (10/11)	93% (40/43)
<b>Reader 2</b>	82% (9/11)	95% (41/43)

Table 1. Sensitivity and specificity data for Inhance compared to CE MRA. Accessory renal arteries not detected by the readers were considered negative for significant renal artery stenosis for calculation of sensitivity and specificity.

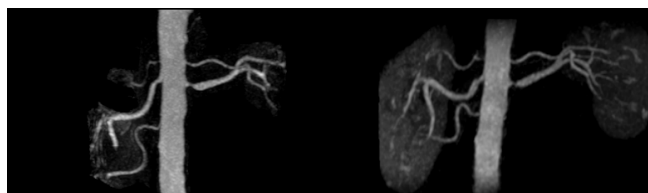


Fig. 1. MIP images from CE MRA (left) and Inhance (right) in patient with 3 right and 2 left renal arteries. Severe stenosis of the superior right accessory and main left renal arteries is clearly demonstrated on the Inhance image.

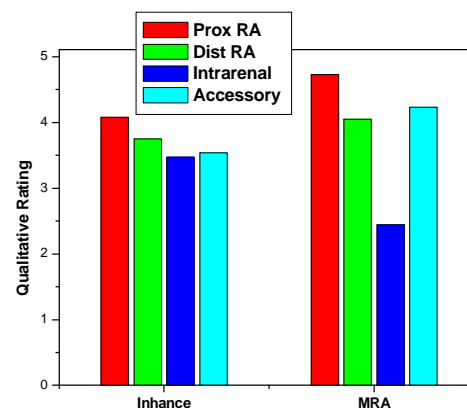


Fig. 2. Image quality ratings of Inhance and CE MRA images for visualization of proximal and distal renal arteries, intrarenal arteries, and accessory arteries (1=uninterpretable, 5=perfect image).

**Discussion:** Preliminary results using a non-contrast respiratory-triggered 3D SSFP sequence for assessment of renal artery stenosis are promising. While image quality ratings were slightly higher for traditional CE MRA images, Inhance images were of good-excellent quality in most cases, and there was good general agreement with CE MRA for detection of significant renal artery stenosis. The major limitation of the Inhance technique is seen in patients with irregular respirations of variable amplitude, which frequently resulted in compromised image quality. A second limitation is that the achievable superior to inferior coverage is constrained by the dependence on the inflow effect of arterial blood, and thus inferior accessory arteries may be missed. Both of these limitations may be overcome by the incorporation of a breath-held 3D SSFP acquisition into the non-contrast renal MRA protocol.