

Intra-individual Comparison of Contrast Enhanced Magnetic Resonance Angiography and Digital Subtraction Angiography of the Lower Extremities

J. T. Heverhagen¹, M. Augsten¹, M. Burbelko¹, A.-C. Stamm¹, M. O. Kalinowski¹, and K. Klose¹

¹Department of Diagnostic Radiology, Philipps University, Marburg, Germany

Introduction: Contrast enhanced MR Angiography (CE MRA) is continuously replacing diagnostic Digital Subtraction Angiography (DSA) in clinical routine. However, DSA remains the reference standard. Therefore, the purpose of this study was to intra-individually compare CE MRA and DSA of the lower extremities in patients with severe peripheral arterial occlusive disease (PAOD).

Materials and Methods: 192 patients (73 female; 119 male; mean age: 70.0 years) were included in this IRB approved trial. All patients underwent run off MRA (1.5T) of both lower extremities for suspected peripheral arterial occlusive disease and DSA of at least one side. Patients received 0.2 mL/kg bodyweight gadobutrol.

Three independent radiologists (two observers reviewed MRA images independently, one observer reviewed DSA images) evaluated the images for image quality and presence, number and severity of stenoses. Image quality was assessed on a five point scale from 1 excellent to 5 non-diagnostic. In addition, the presence of venous opacification was assessed on a 5 point scale from 1 no venous opacification to 5 venous enhancement stronger than arterial enhancement. Severity of stenoses was evaluated on a 5 point scale (1: no stenosis; 2: diameter stenosis below 51%; 3: 51% to 70%; 4: 71% to 99%; 5: occlusion). In addition, stenoses were classified in non-significant (grades 1, 2 and 3) and significant (4 and 5). Sensitivity and specificity were calculated for both MRA observers with DSA as standard of reference. Interobserver variation as assessed by a Cohen's kappa statistic.

Results: Median image quality of the MRA images was rated as good (2) from both observers. Venous opacification was rated non-influential on diagnosis in 99% of cases. Sensitivity and specificity for observer 1 (2) were 98% (95%) and 96% (99%). The Cohen's kappa statistic revealed a significant almost complete agreement of 0.88.

Conclusion: State of the art run off MRA of the lower extremities for suspected PAOD provides excellent sensitivity and specificity. It is user independent proven by a Cohen's kappa of 0.88. State of the art run off MRA of the lower extremities may replace diagnostic DSA for suspected PAOD as an user independent, accurate application.

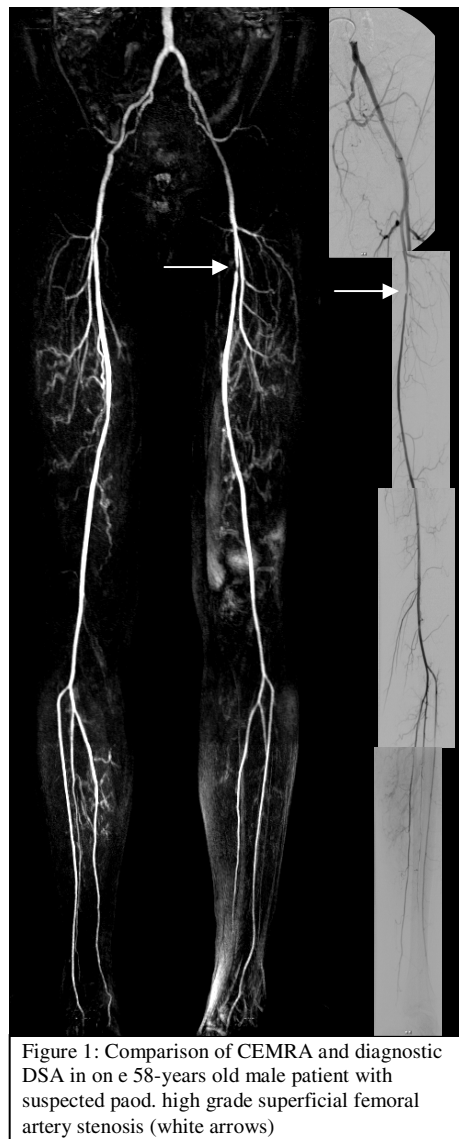


Figure 1: Comparison of CEMRA and diagnostic DSA in one 58-year-old male patient with suspected PAOD. High grade superficial femoral artery stenosis (white arrows)