

Distribution of Intraplaque Calcification in the Femoral Artery: a Multi-Contrast MRI Study

F. Li¹, C. Yuan¹, M. Ferguson¹, D. Xu¹, X. Zhao¹, and M. M. McDermott²

¹University of Washington, Vascular Imaging Lab, Seattle, WA, United States, ²Northwestern University's Feinberg School of Medicine, Chicago, IL, United States

Background: Identifying the distribution of intraplaque components is helpful for predicting the prognosis of atherosclerosis plaques¹⁻². There are, however, only limited studies conducted on peripheral artery lesions with existing imaging techniques. The aim of this study is to investigate the distribution of intraplaque calcification (CA) in femoral arteries using multi-contrast MRI.

Methods: Thirteen patients with an Ankle-Brachial Index less than 1.00 were scanned with multi-contrast MRI (2D TOF, T1WI, PD and T2WI) on a 1.5T scanner (Siemens, Sonata). The scan covered the common femoral artery (CFA) and the proximal segment of the superficial femoral artery (SFA). Multi-contrast cross-sectional images of common and proximal superficial femoral arteries were matched using the bifurcation of common femoral artery as a landmark and independently interpreted by two reviewers. The lumen area (LA), total vessel area (TVA) and calcified regions in the artery were outlined using custom software (CASCADE), using previously published image analysis criteria³. Wall area (WA=TVA-LA) and Normalized Wall Index (NWI=WA/TVA) were calculated. NWI is a measure of plaque burden that takes into account the varying size of the vessel (CFA vs. SFA)⁴.

Results: (1) Plaques were identified in all cases. Thirty-seven slices were excluded due to poor image quality. The remaining 171 slices included 44 CFA and 127 SFA slices. The prevalence of calcification was significantly higher in common femoral (72.7% [32/44]) compared to superficial femoral artery slices (33.1% [42/127]; $P < 0.01$; Fig 1). Furthermore, the mean CA area was greater in the CFA than in the SFA, measuring 6.16 (95%CI, 4.55–7.84) and 1.18 (0.84–1.75) mm², respectively ($P = 0.015$). CFA also had a bigger CA burden (CA area/wall area*100) than SFA (10.57% vs. 2.85%, $P < 0.01$; Fig 2). (2) Mean NWI of all slices was 0.72±0.10. The slices were divided into tertiles according to NWI. The mean CA areas in slices of NWI <0.68, 0.68–0.76, >0.76 (group 1, 2, 3) were 0.90 (95%CI, 0.36–1.44), 2.85 (1.54–4.17) and 4.05(2.85–5.25) mm², respectively. A statistically significant difference ($P < 0.01$) was detected across the three groups, and between the paired groups 1 and 2 ($P = 0.024$) and 1 and 3 ($P < 0.01$). No significant difference was detected between groups 2 and 3 ($P = 0.68$). Similarly, the mean CA burden was 1.85%, 5.58% and 7.36% in three groups, and the difference was also statistically significant ($P < 0.01$; Fig 3, 4).

Conclusion: The distribution of calcification in femoral artery atherosclerosis is strongly associated with the arterial segment and plaque burden. This heterogeneous distribution may reflect differences in the initiation and progression of peripheral artery disease by site. Future studies looking at the frequency of other plaque components are warranted.

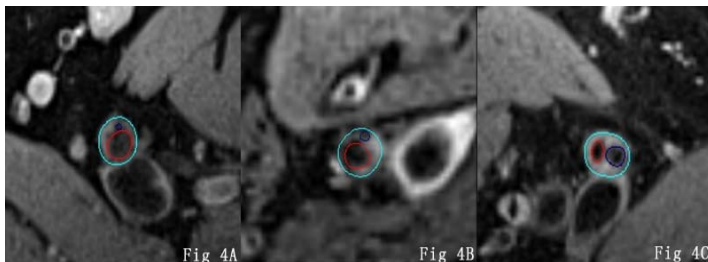
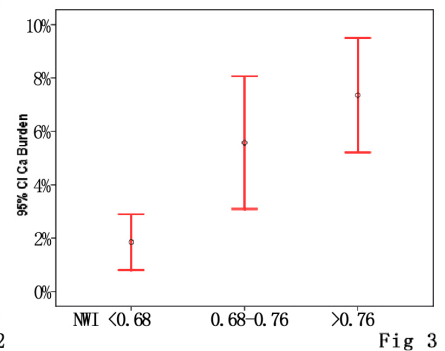
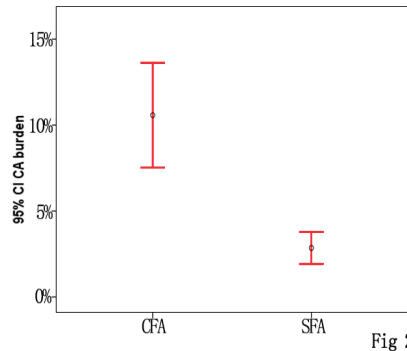
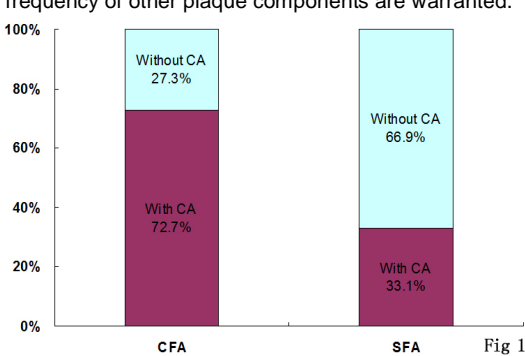


Fig 1 Comparison of the frequency of calcification (CA) in cross-sectional images of common and superficial femoral arteries (CFA and SFA).

Fig 2 Shows the difference of CA burden in the CFA and SFA. Statistically significant differences were detected between the two segments ($P < 0.01$). CFA had a bigger CA burden than SFA.

Fig 3 Comparison of CA burden in different NWI groups. A statistically significant difference occurred between the three groups ($P < 0.01$).

Fig 4A, 4B, 4C are cross-sectional proton density-weighted images of the femoral artery with a NWI of 0.65, 0.70, 0.88. The CA burdens are 2.64%, 4.73% and 20.76%, respectively. (Outer wall-light blue; Lumen- red circle; Calcification – dark blue).

Reference:

1. Cappendijk VC, et al. J Magn Reson Imaging, 27: 1356-1361, 2008.
2. Saam T, et al. Radiology, 240: 464-472, 2006.
3. Saam T, et al. Arterioscler Thromb Vasc Biol, 25: 234-239, 2005.
4. Kerwin W, et al. Top Magn Reson Imaging, 18: 371-378, 2007.