

MR plaque image: prediction of the complication risk at carotid artery stenting.

M. Sakamoto¹, T. Taoka¹, H. Nakagawa¹, K. Takayama², T. Wada², K. Myouchin¹, T. Miyasaka¹, T. Akashi¹, and K. Kichikawa¹

¹Radiology, Nara Medical University, Kashihara, Nara, Japan, ²Ishinkai Yao General Hospital

Introduction

The information of carotid plaque component evaluated by MR plaque image is important as well as luminal diameter because embolic sources from ruptured vulnerable plaque causes infarction. During carotid artery stenting (CAS) using filter-type protection device, flow impairment of internal carotid artery is sometimes observed and associated with the excess risk of periprocedural stroke. The cause of slow flow is seemed to be embolic sources derived from ruptured plaque, so it is expected that the occurrence of this “slow flow phenomenon” is predicted by evaluating the composition and vulnerability of carotid plaque. The purpose of this study is to investigate the feasibility of MR plaque image as the predicting factor of slow flow phenomenon at CAS.

Materials and Methods

Thirty-one carotid artery stenotic lesions of 30 patients (27 males and 3 females, average age: 71.8) were treated by CAS since Oct 2007 to Jul 2008. All cases underwent CAS within one week after being evaluated by MR plaque image. Cross-sectional images of common to internal carotid artery were obtained with black blood T1, T2 weighted and time-of flight sequences. We calculated signal intensity ratio of main plaque component area compared with ipsilateral sternocleidomastoid muscle and judged the plaque component from signal ratio pattern. We classified carotid plaque compositions into vulnerable group (Intraplaque hemorrhage (IH) and Lipid rich/Necrotic core (LR/NC)) and stable group (Loose matrix (LM), Fibrous tissue (F), and Dense calcification (DC)). The correlation between plaque composition groups and occurrence of slow flow phenomenon during CAS was analyzed using kai-square test.

Results

The distribution of main carotid plaque components was 15 vulnerable plaques (IH: 10 and LR/NC: 5), and 16 stable plaques (LM: 11, F: 2 and DC: 3). The “slow flow phenomenon” was observed at 10 CAS procedures (flow arrest: 5 and slow flow: 5). The plaque features of 5 flow arrest lesions were 4 vulnerable (4 IH) and 1 stable (LC), and that of 5 slow flow lesions were 3 vulnerable (3 IH) and 2 stable (2 LC). There was significant difference ($P<0.05$) on chi-square test between the vulnerable and stable plaque groups about the occurrence of slow flow phenomenon.

Conclusion

The carotid plaque classified the composition as vulnerable, especially intraplaque hemorrhage by MR plaque image has the significant higher risk of slow flow phenomenon at CAS than other plaque compositions. In performing CAS, the risk of complication can be predicted and reduced by taking good use of the information of plaque compositions evaluated by MR plaque image.

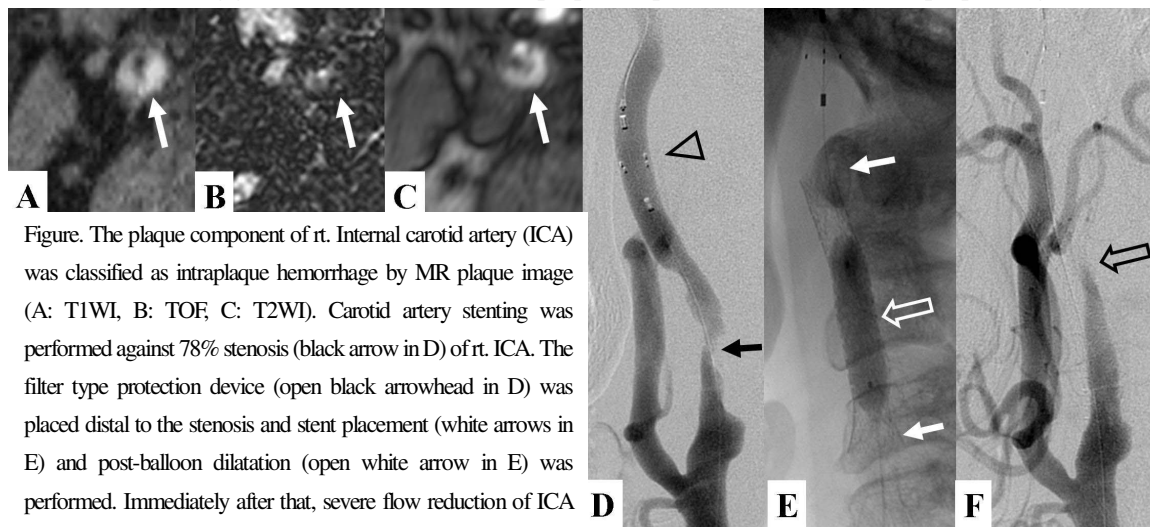


Figure. The plaque component of rt. Internal carotid artery (ICA) was classified as intraplaque hemorrhage by MR plaque image (A: T1WI, B: TOF, C: T2WI). Carotid artery stenting was performed against 78% stenosis (black arrow in D) of rt. ICA. The filter type protection device (open black arrowhead in D) was placed distal to the stenosis and stent placement (white arrows in E) and post-balloon dilatation (open white arrow in E) was performed. Immediately after that, severe flow reduction of ICA was observed (black open arrow in F).