

Anti-Aliasing Acquisition (AAA) Decreases Study Duration While Maintaining Accuracy in Cardiac MR Flow Exams

J. D. Green^{1,2}, D. J. Patton², and Q-S. Xiang³

¹Siemens Healthcare, Calgary, Alberta, Canada, ²University of Calgary, Calgary, Alberta, Canada, ³University of British Columbia, Vancouver, British Columbia, Canada

Introduction: Flow imaging is an important tool in clinical cardiac MRI. However, choosing the appropriate velocity encoding (venc) can be challenging: too little sensitivity leads to a low velocity-to-noise ratio (VNR); too much sensitivity causes velocity aliasing. Because complicated anatomy and pathology can make it difficult to accurately predict the appropriate venc in advance for a given patient, clinicians are often forced to repeat flow quantification scans several times in an exam to ensure that the venc is low enough to ensure a high VNR but high enough to prevent aliasing. This prolongs the exam.

A previously demonstrated technique, Anti-Aliasing Acquisition (AAA) (1), eliminated the redundancies in the conventional flow quantification technique to acquire consistently unaliased images while still using a low venc (ensuring high VNR) and only 2 k-space acquisitions per image. Using AAA, clinicians should be able to choose one lower venc but not see velocity aliasing in most cases. Our hypothesis was that application of AAA to a cohort of patients referred for MR flow quantification should reduce overall study duration while still maintaining sufficient VNR/accuracy when compared to a conventional protocol.

Methods: All studies were performed on a 1.5 T MAGNETOM Avanto (Siemens Healthcare, Erlangen, Germany). Studies were performed in patients (n=5) referred to our centre for aortic flow assessment. An AAA sequence, as described previously (1), was implemented by modifying a conventional segmented, prospectively-triggered, cine gradient echo flow quantification sequence. The AAA sequence used a small venc (high velocity sensitivity) of 80 cm/s in every cine frame. In addition, each cine frame also used a large venc (small velocity sensitivity), with even phases using a venc of -400 cm/s and odd phases using a venc of +400 cm/s. Using previously described algorithms to combine the large and small venc data sets (1,2), the final AAA data set contained a single, unaliased cine data set.

Patients recruited to this study underwent their standard clinical exam, which involved basic localization of a cross-section of the aorta, followed by imaging with the conventional flow quantification sequence. As per our clinical protocol, patients were scanned multiple times with the conventional technique. Using the patient's history and their knowledge of cardiac anatomy, the clinician chose a starting value for the venc (typically 100 – 160 cm/s), then adjusted it up or down to determine the smallest value which could be used without seeing velocity aliasing in the image. We recorded the number of scans required to obtain the correct venc using the conventional scan, then scanned the patient once in the same slice position using AAA with only the vencs described above (80 cm/s; ± 400 cm/s). Typical sequence parameters for both sequences were: TR/TE/flip angle=6.1 ms/3.0 ms/25°; FOV=244 x 340 mm²; matrix=138x256; slice thickness = 6 mm; 3 lines acquired per cardiac cycle; non-breath hold; 2 averages; temporal resolution = 36.6 ms. After completing the study, regions of interest were drawn in the aorta in each phase. We measured the maximum, minimum, and mean flow for each patient using each technique, and evaluated the reliability of the AAA measurements using Cronbach's Alpha.

Results: Conventional and AAA flow imaging were successful in all patients. Comparison of the three evaluated metrics is summarized in Figure 1. The correlation using Cronbach's Alpha for mean flow, maximum flow, and minimum flow was 0.999, 0.999, and 0.999 respectively. Typical images are shown in Figure 2. Using the conventional technique, an average of 3.8 scans was required per exam. The average time for a flow scan was 82 s. Multiplying each patient's scan time by the number of conventional flow required to complete the exam minus one, the mean hypothetical time that would be saved by only running the AAA sequence was 210 s \pm 18 s (not counting the time required to adjust parameters between scans and give the patient instructions).

Discussion and Conclusion: The AAA technique successfully removed velocity aliasing in all cases, and was able to accurately quantify flow in a single flow quantification scan. In contrast, the conventional sequence took between 3 and 5 scans to accomplish the same objective, and on average required 3.5 minutes of additional scanning. We conclude that AAA can act as a time saving measure whenever flow quantification is required as part of a clinical cardiac exam and still maintain accuracy.

References

- (1) Xiang, Q-S. *Proc. Intl. Soc. Magn. Reson. Med.* 9 (2001).
- (2) Lee, A.T. et al. *Magn Reson Med* 33 (1995).

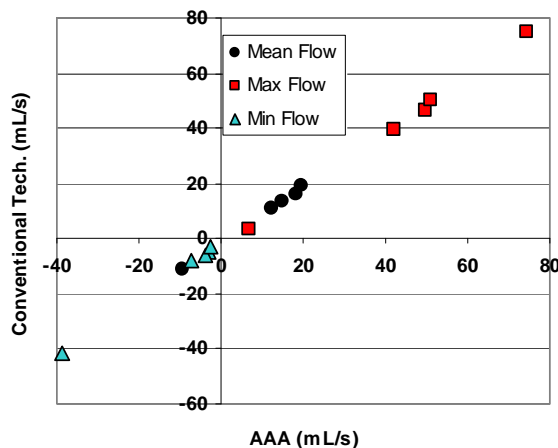


Figure 1: Plot of mean flow, maximum flow, and minimum flow measured from conventional technique data sets vs. the same quantities measured with AAA data sets

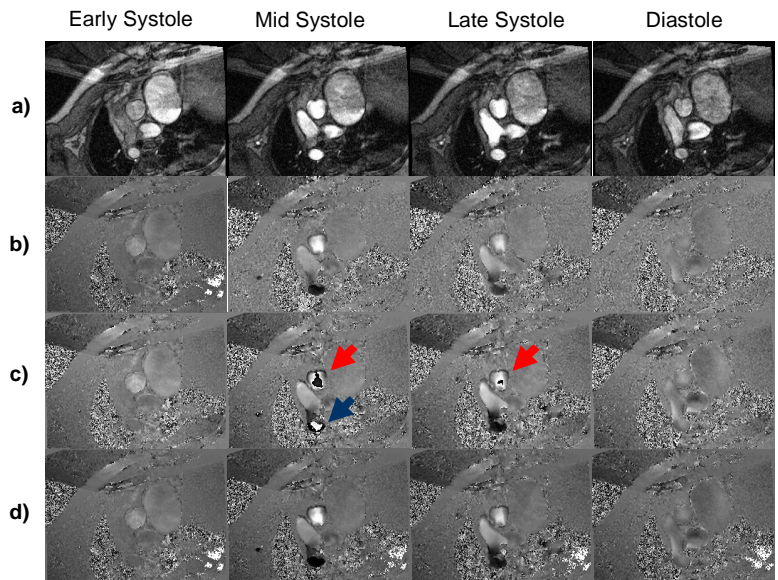


Figure 2: Select images from one patient at the same early-, mid-, and late systolic phases, and a diastolic phase. **a)** Magnitude images. **b)** Conventional flow quantification; venc = 120 cm/s. **c)** Intermediate AAA images before postprocessing, venc = 80 cm/s. Note large velocity aliasing in mid and late systole in both aortic root (red arrow) and descending aorta (blue arrow). **d)** Final AAA images, venc = 80 cm/s. Velocity aliasing is no longer present.