

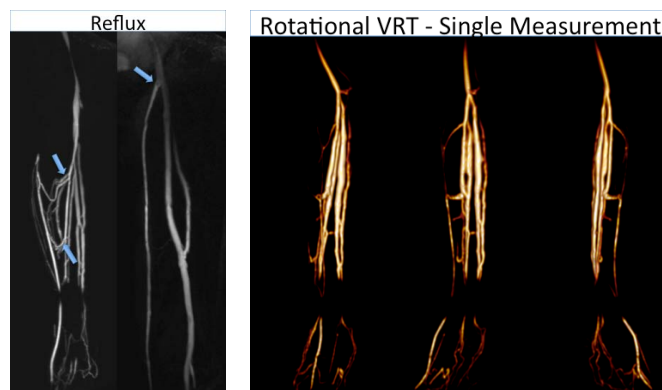
DYNAMIC EVALUATION OF LOWER EXTREMITY VARICOSITIES: PRELIMINARY EXPERIENCE WITH ISOTROPIC TIME-RESOLVED DIRECT MAGNETIC RESONANCE VENOGRAPHY (TR-MRV) AT 3 TESLA.

D. G. LOHAN¹, R. SALEH¹, S. HSU¹, C. LOH¹, S. T. KEE¹, D. ENNIS¹, G. LAUB¹, and J. P. FINN¹
¹RADIOLOGY, DAVID GEFKEN SCHOOL OF MEDICINE AT UCLA, LOS ANGELES, CA, United States

INTRODUCTION: Laser/radiofrequency thermal ablation has generated renewed enthusiasm regarding imaging options for lower extremity varicose veins. However, central to their success is the assumption that pre-operative evaluation, using Duplex Doppler sonography, provides a reliable anatomic and functional map of this complex, variable vascular system. Such time-consuming cartography (often in excess of 60 minutes) places considerable demands upon both the technician and patient. Failure of identification of even a single incompetent perforating vein may result in recurrent varicosities. We describe a novel, rapid approach using dynamic MRA capable of challenging sonography as the reference standard for pre-operative varicose vein imaging.

MATERIALS AND METHODS: All TR-MRV examinations were performed on a Siemens Trio 3T MR system. A 24-gauge cannula was sited within one of the superficial dorsal veins of the foot on the affected side and connected to an injector pump containing 160mL of a 1:40 solution of gadolinium and saline. A tourniquet was applied immediately above the ankle joint level at a pressure sufficient to produce superficial venous occlusion, prompting isolated deep venous filling. A separate tourniquet above the knee joint level prevented rapid central dissipation of injected solution. The imaging protocol included dynamic time-resolved 3D MR venography (TWIST) from the ankle to above the knee joint during infusion of 50mL dilute Gd (1/40) at 0.8mL/sec. (FOV: 500x360mm, Voxel Size 1.2x1.0x1.2mm, TR/TE/Flip Angle 2.7ms/1.1ms/21°, Bandwidth 650Hz/Pixel, GRAPPAx3, Partial Fourier 6/8 along all three axes, Acquisition Time 3.5s per 3D slab, Measurements 14). The supra-geniculate tourniquet was then released and a second dynamic acquisition performed, incorporating from the superior aspect of the calf station to the inguinal ligament during injection of 80mL of the remaining contrast solution, at 1.0mL/sec.

RESULTS: TR-MRV provided dynamic contrast opacification of the lower extremity deep venous system (Fig. 1), allowing confident identification of the presence and location of incompetent venous reflux into the superficial venous system. In providing multiple, sequential isotropic datasets, TR-MRV facilitates retrospective data processing with maximum intensity projection (MIP) and volume-rendered reconstruction (Fig. 2), of vital importance in evaluating this complex anatomic region.



CONCLUSION: Direct TR-MRV of the lower extremity provides dynamic functional and anatomic information regarding the lower extremity deep venous system and has the potential to supplement or replace duplex Doppler sonography in the pre-operative evaluation of patients with varicosities related to incompetent perforating veins.