

Computer-aided method for automated selection of optimal imaging plane for measurement of cerebral volumetric blood flow rate by MRI

P.-Y. Teng¹, and N. Alperin¹

¹University of Illinois, Chicago, IL, United States

Purpose

The aim of this study is to develop a computer-aided method for finding an optimal imaging plane for simultaneous measurement of the arterial blood inflow through the four blood vessels supplying the brain by phase contrast MRI (PCMRI). Quantification of blood flow by PCMRI is becoming more widely used for noninvasive measurement of total cerebral blood flow (CBF) and intracranial pressure [1, 2]. The PCMRI measurement requires identification of a plane that is perpendicular to the main direction of the blood vessel to reduce measurement error. Currently commonly used method for measurement of total CBF employ 4 separate scans to measure the blood flow through each of the 4 main blood vessels supplying the brain (internal carotid (ICA) and vertebral arteries(VA)) [2]. The overall set up and scan time can be considerably shortened if a plane that is nearly perpendicular to all 4 vessels can be identified automatically. The requirements for that plane are: a) the location of the imaging plane should be as close but below the foramen magnum, b) the imaging plane should intersect the ICAs and VAs, and c) the orientation of the imaging plane should be as perpendicular to the 4 vessels at the intersections as possible.

Currently, when one scan is used to measure the flow simultaneously in all 4 vessels, the imaging plane is selected manually by drawing a line on projection views of the neck vessels obtained with MRA (Fig. 1.1). The preferred location for the imaging plane (dashed line in Fig 1.1) is as close but below the level where the VAs enter the foramen magnum. In general, this range is within two C-shape curves where the VAs pass through the transverse foramina at C2 and C1 vertebrae (white arrows in Fig. 1.1). The task of manually selecting an imaging plane that is nearly perpendicular to all vessels is not trivial and often, manual selection of the imaging plane may not yield the optimal imaging plane.

Methods

Automated identification of the optimal imaging plane involves three steps. *a) Centerline Extraction:* The centerline extraction method [3] is based on distance maps. Two distance maps, the single point seeded distance map (SS-map) and the boundary seeded distance map (BS-map), are first created for each selected vessel segment. Each point within the vessel in the SS-map corresponds to the length of the shortest path to the vessel origin. For the BS-map, each point within the vessel corresponds to the shortest distance to the vessel boundary. The centerline can be extracted by traversing through descending values in the SS-map, while using the local values in the BS-map to ensure the centeredness of the centerline. *b) Identification of the VA segments passing C2 and C1 vertebrae:* First, a main flow direction is identified based on the global direction of the ICAs which tend to curve less than the VAs. The segments of the VAs passing C2 and C1 vertebrae are then identified by quantifying the direction of the VAs relatively to the main flow direction. For each point in the VA centerlines, the deviation angle from the main flow direction is calculated (Fig 1.2). The two local maxima of the deviation curve is used to locate the level where the VA curves to pass through the C2 and C1 transverse foramina, where this segment is used as the search region for locating the optimal imaging plane. *c) Optimal Imaging Plane Calculation:* The optimal imaging plane is then identified by minimizing the error value defined by $\sum_{k=1}^4 (1 - \cos \theta_k)$, which is a weighted sum of the angles (θ s) between the plane's normal and the vessel directions

at the intersections of the vessel centerlines. The plane with the minimum error value is considered as the optimal imaging plane.

The performance of the CAM was evaluated using six MRA datasets. For each dataset, the error value of the imaging plane identified by the CAM was compared with that of the plane which was selected by a radiologist. The distribution of the angles between the vessel direction and the plane's normal obtained using the CAM and the radiologist's manual selections were compared.

Results

The error values found by the CAM and the radiologist for each of the six datasets are shown on Fig 1.3. A statistically significant smaller error was obtained by the CAM ($P < 0.01$, Student's t-test). The mean \pm SD of the error values obtained by the CAM and the radiologist are 0.074 ± 0.056 and 0.267 ± 0.134 , respectively. The error values of the imaging planes selected by the CAM were all lower than those selected by the radiologist. The distribution of the plane intersection angles (θ s) is shown on Fig 1.4. The mean \pm SD of θ s obtained by the CAM and the radiologist are 9.3 ± 6.1 and 17.7 ± 12.0 respectively. When the CAM was used, only 8.3% of the vessels assessed had θ s above 20 degrees compared with 33.3% when imaging planes were selected by the radiologist. The processing time of the CAM implemented in IDL (Boulder, CO) takes approximately two minutes on an Intel Core 2 Duo 1.86GHz desktop with 2GB RAM.

Conclusion

A CAM for automated selection of an imaging plane in the upper neck that is nearly perpendicular to the 4 blood vessels leading blood to the brain has been developed. The CAM outperformed manual selection by an experienced observer. Automatically identified imaging planes had consistently and considerably smaller error values and plane intersection angles (θ s) compared to planes selected by the radiologist. A reliable automated method for selection of imaging plane for cerebral blood flow measurements by MRI will potentially lead to reduced measurement error due to smaller plane intersection angles and to shorter scan time by eliminating the need for 4 separate scans.

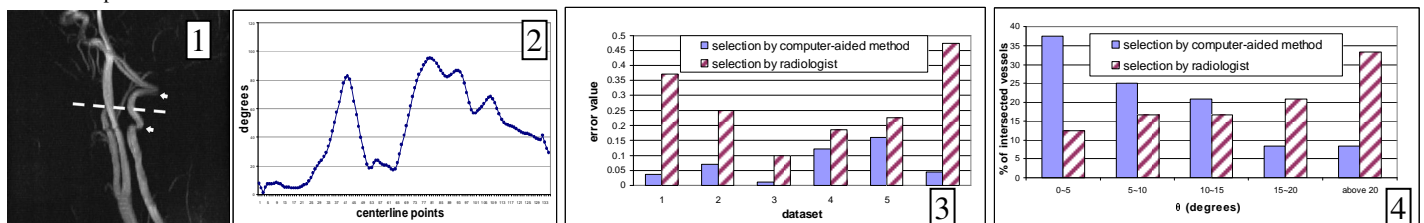


Figure 1. A sagittal view of an MRA at the neck region(1); An example of the VA deviation curve(2); The error values(3), and the distribution of the intersection angles(4) of the imaging planes selected by the CAM(solid) and the radiologist(stripped).

References

- [1] Alperin N., Lee S.H., Loth R., Raksin P.B., and Lichtor T. MR-Intracranial Pressure (ICP): A Method to Measure Intracranial Elastance and Pressure Noninvasively by Means of MR Imaging: Baboon and Human Study. *Radiology*. 217 (3):877-885:2000.
- [2] Zhao M., Charbel F.T., Alperin N., Loth F., Clark M.E., Improved phase-contrast flow quantification by three-dimensional vessel localization, *Magnetic Resonance Imaging*. 18(6):697-706:2000
- [3] Jiang H., Alperin N., A new automatic skeletonization algorithm for 3D vascular volumes, *Proceedings of the 26th Annual International Conference on IEEE Engineering in Medicine and Biology Society*. 1:1565-1568:2003