

## High-field Diffusion Tensor Imaging on a mouse model of Leukoencephalopathy

Y. van de Looij<sup>1,2</sup>, G. Favrais<sup>3</sup>, P. Gressens<sup>3</sup>, P. S. Hüppi<sup>1</sup>, R. Gruetter<sup>2,4</sup>, and S. V. Sizonenko<sup>1</sup>

<sup>1</sup>Division of Child Growth & Development, Department of Pediatrics, University of Geneva, Geneva, Switzerland, <sup>2</sup>Laboratory for Functional and Metabolic Imaging, Ecole Polytechnique Fédérale de Lausanne, Lausanne, Switzerland, <sup>3</sup>INSERM-UMR676, France, <sup>4</sup>Department of Radiology, University of Geneva and Lausanne, Switzerland

### Introduction:

On early preterm infants, diffuse and focal white matter injury is one of the predominant forms of brain damage. Leukoencephalopathy occurs primarily in the white matter of the brain and involves defects in either the formation or the maintenance of the myelin sheath. The mechanisms of this pathology are still unknown. The aim of this work was to study mechanisms of leukoencephalopathy on a mouse model obtained by interleukin (IL-1 $\beta$ ) injection by the way of diffusion tensor imaging (DTI) and histopathology.

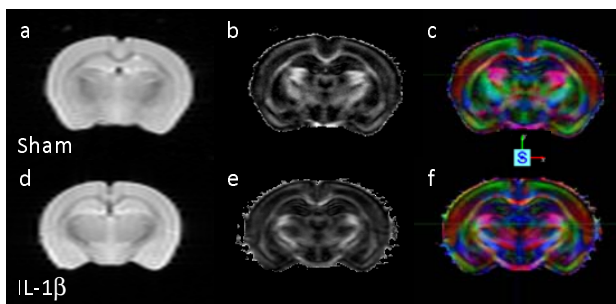
### Material and Methods:

1-day after birth (P1), mice were treated by intraperitoneal injection of IL-1 $\beta$  (40ng, IL-1 $\beta$  group) or saline solution (Sham group) twice a day from P1 to P5. At P35, mice were sacrificed and brains were formalin-fixed for subsequent ex vivo MRI and histology. All experiments were performed on an actively-shielded horizontal 9.4T/31cm magnet (Varian/Magnex) equipped with 12-cm gradient coils (400mT/m, 120 $\mu$ s) with a transmit-receive 25-mm birdcage RF coil. After manually adjustment of the first and second order shims (water linewidth ~ 20 to 40 Hz) spin Echo sequence with addition of the Stejskal-Tanner diffusion gradients was used. Diffusion gradients were applied along twelve spatial directions: (x, y, 0), (x, -y, 0), (x, 0, z), (x, 0, -z), (0, y, z), (0, y, -z) as well as the six opposite directions to cancel cross terms (Neeman M. et al. MRM 1991). Intensity, duration and diffusion time were set to 22 G/cm, 3 ms and 20 ms respectively, given a b-value of 1659 s.mm<sup>-2</sup>. A field of view of 20  $\times$  20 mm<sup>2</sup> was sampled on a 128  $\times$  64 cartesian grid, given an in-plane pixel size of 156  $\mu$ m. Multi-slice DT images were acquired (20 slices of 0.8 mm thickness) in the axial plane with 6 averages and TE/TR = 30/5000 ms. Using in house software written in Matlab (Mathworks, Natick, MA), diffusivity values (D<sub>AV</sub>, D<sub>||</sub> and D<sub>⊥</sub>) as well as FA was derived from the tensor. The program allows manual delineation of region of interest (ROI) on the FA maps. Three different regions of the brain were analyzed: the corpus callosum (CC), the superficial layer of sensori-motor cortex (SCx) and the basal ganglia (BG). The brains were subsequently processed for the study of the Proteo-Lipid-Protein (PLP) and the Myelin-Basic-Protein (MBP) distribution by immunostaining on 10  $\mu$ m-thick sections. In parallel, the aspect of myelin sheath and axons was analyzed by electron microscopy (EM) on coronal sections at the cingulum level. Significant differences of diffusivity and FA values between IL-1 $\beta$  and Sham groups were assessed by a Mann Whitney test.

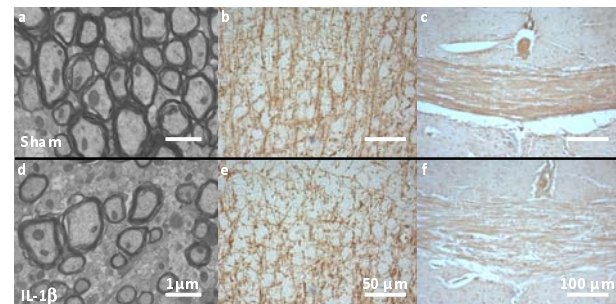
### Results:

**DTI:** (Fig. 1) in the CC, IL-1 $\beta$  group show significant decrease of FA (IL-1 $\beta$ : FA = 0.63  $\pm$  0.04, Sham: FA = 0.74  $\pm$  0.01, p = 0.008) and increase of D<sub>⊥</sub> (IL-1 $\beta$ : D<sub>⊥</sub> = 13.4  $\times$  10<sup>-05</sup>  $\pm$  1.58  $\times$  10<sup>-05</sup>, Sham: D<sub>⊥</sub> = 9.66  $\times$  10<sup>-05</sup>  $\pm$  1.11  $\times$  10<sup>-05</sup> s/mm<sup>2</sup>, p = 0.008) compared with Sham group. In the superficial layer of the SCx, FA values were not significantly different in the two groups, but D<sub>⊥</sub> was significantly increased in the IL-1 $\beta$  group compared with Sham group (IL-1 $\beta$ : D<sub>⊥</sub> = 21.2  $\times$  10<sup>-05</sup>  $\pm$  0.81  $\times$  10<sup>-05</sup>, Sham: D<sub>⊥</sub> = 19.5  $\times$  10<sup>-05</sup>  $\pm$  1.05  $\times$  10<sup>-05</sup>, p = 0.032). In the BG, D<sub>AV</sub> value was found significantly increased in the IL-1 $\beta$  group compared with Sham group (IL-1 $\beta$ : D<sub>AV</sub> = 23.9  $\times$  10<sup>-05</sup>  $\pm$  1.22  $\times$  10<sup>-05</sup>, Sham: D<sub>AV</sub> = 21.9  $\times$  10<sup>-05</sup>  $\pm$  0.77  $\times$  10<sup>-05</sup>).

**Histology:** (Fig. 2) the densitometric analyze of the PLP staining revealed a decrease of the amount of PLP in the overall white matter (CC, external capsule, anterior commissura and BG) at P35 in the IL-1 $\beta$  group. In parallel, a reduction of the MBP density was only noticed at the cortical level, associated with a dramatic change in the myelin-associated axonal fiber orientation in the SCx. Surprisingly, the morphological aspect of the myelin sheath is similar in our two experimental groups (compaction, G-ratio) but the non-myelinated axons are largely more numerous in the IL-1 $\beta$  group. Furthermore, the neonatal exposition to IL-1 $\beta$  leads to a defect of the axon outgrowth as revealed by the measure of the myelinated axon diameter (AD) (IL-1 $\beta$ : AD = 0.43  $\pm$  0.17  $\mu$ m vs. Sham: AD = 0.5  $\pm$  0.2  $\mu$ m, p < 0.001).



**Fig. 1:** T<sub>2</sub>W images (a,d), FA (b,e) and direction encoded color maps (c,f) of a typical Sham (up) and IL-1 $\beta$  (down) mouse brain.



**Fig. 2:** EM (a,d), MBP (b,e) and PLP (c,f) staining in the CC (a,d,c,f) and in the SCx (b,e) of a typical Sham (up) and IL-1 $\beta$  (down) mouse brain.

### Discussion and conclusion:

It should be noticed that here are ex-vivo data, i.e. diffusivity values are significantly lower than in-vivo. FA and D<sub>⊥</sub> changes after IL-1 $\beta$  in the CC are correlated with histology and EM, showing decreased FA and increased orthogonal diffusivity which in EM is represented by a decrease of axonal diameter i.e. an increase of inter-axonal space. The SCx is a less anisotropic region (FA ~ 0.25 in the superficial layer) with a radial organization, in this area the IL-1 $\beta$  group showed a decrease of optical density with MBP staining which correlated with an increase of D<sub>⊥</sub>. These correlations provide evidence for a quantitative myelination defect. In the BG, low anisotropic media (FA ~ 0.17), myelin deficit could be responsible for a larger mobility of water molecules explaining the D<sub>AV</sub> increase in the IL-1 $\beta$  group. The conclusions of this work are: 1. IL-1 $\beta$  mouse model is an excellent model of leukoencephalopathy and gives a better understanding of leukoencephalopathy mechanisms. 2. DTI results correlated with histology provide evidence for a quantitative and diffuse myelination defect and a decrease of axonal diameter. 3. For tissues with complex microstructure and high cellular density such as BG and SCx where FA tends to be low, diffusivity values indicate changes in microstructure more accurately than FA.

**Acknowledgements:** Supported by NEOBRAIN Consortium, European Commission, ELA foundation and PremUP (Paris-France), the Centre d'Imagerie Biomédicale (CIBM) of the UNIL, UNIGE, HUG, CHUV, EPFL, the Leenards and Jeantet Foundation and the Fond National Suisse (Switzerland).