

# Probabilistic Corticocortical Connectivity Maps of Human Brain based on DTI Tractography and Cortical Parcellation

H. Huang<sup>1</sup>, J. L. Prince<sup>2</sup>, A. Carass<sup>2</sup>, B. Landman<sup>3</sup>, P. C. van Zijl<sup>4,5</sup>, and S. Mori<sup>4,5</sup>

<sup>1</sup>Advanced Imaging Research Center, UT Southwestern Medical Center, Dallas, TX, United States, <sup>2</sup>Electrical and Computer Engineering, Johns Hopkins University, Baltimore, MD, United States, <sup>3</sup>Biomedical Engineering, Johns Hopkins University, Baltimore, MD, United States, <sup>4</sup>Radiology, Johns Hopkins University, Baltimore, MD, United States, <sup>5</sup>F.M. Kirby Functional MRI Center, Kennedy Krieger Institute, Baltimore, MD, United States

## Introduction

Corticocortical connectivity plays a pivotal role in brain function and may be impaired in several neurological or psychiatric diseases. The connectivity substrate is the white matter axon. DTI-based tractography can be used for noninvasive tracing of the white matter axons, including association tracts connecting different cortical areas. However, without accurate cortical parcellation, it is difficult to define the cortical areas that are connected. Diffusion imaging approach has been used to determine the network of the brain [1,2] and delineate the peripheral white matter [3]. In this study, we focused on mapping the cortical surface from specific cortical regions to others. We started with cortical mapping from a lobe. With the fused information from cortical parcellation and DTI-based tractography, the mapping of association tracts from a specific cortical lobe to other cortical areas can be used to set up quantitative corticocortical connectivity maps which indicate how likely a cortical region is connected to another specific cortical region. Cortical parcellation was used to label the cortical lobes for regions of interests in DTI tractography. Four reproducibly traced short association tracts, namely, frontoparietal, parietooccipital, parietotemporal and occipitotemporal tracts, connecting different lobes were also identified. Probabilistic corticocortical connectivity maps were established by nonlinearly registering the connectivity results from ten subjects to a template space. These probabilistic connectivity maps can serve as important structural connectivity reference for fMRI and the study of disease.

## Methods

**Data acquisition:** In vivo adult human data (n=10) were acquired using a 1.5 T Philips Gyroscan NT system. A single-shot EPI sequence with the SENSE parallel imaging scheme (SENSE, reduction factor R = 2.5) was used for DTI data acquisition. DWI parameters were: FOV=240/240/125mm, in plane imaging matrix = 96x96, axial slices thickness = 2.5 mm, parallel to the anterior-posterior commissure line, 30 independent diffusion weighted directions with b-value = 700 sec/mm<sup>2</sup>, 5 additional images with minimal diffusion weighting. Co-registered magnetization-prepared rapid gradient echo (MPRAGE) images were also acquired for cortical parcellation. **Semi-automated cortical parcellation:** An automated topology-preserving method [4] was used for generation of the inner cortical surface defined as gray and white matter boundary. To guarantee initiation of tracking, this inner surface was shrunk by 5mm perpendicular to the surface. We used the inflated cortical surface to manually segment different cortical lobes to ensure accuracy of cortical parcellation. **DTI tractography:** Fiber tracking was based on a linear line propagation model (FACT) [5] with FA threshold 0.2 and angle threshold 40°. Two ROIs were used with “AND” operation [6, 7] \*\*refer to atlas and Wakana paper too. **Probabilistic cortical mapping:** An 8-mm diameter sphere was generated with the end point of the tract as the center to project the fiber to the cortical surface. A probabilistic cortical mapping was generated by nonlinearly registering the cortical maps of each subject to a template space.

## Results

**White matter tracts connecting different lobes:** Table 1 lists association white matter tracts connecting between the principal cortical lobes, including four short association tracts shown in Fig. 1. Among the major long association tracts, superior longitudinal fasciculus (SLF) is the only one connecting more than two lobes. SLF fibers have one end terminating in the frontal lobe and the other ends projecting to parietal and temporal lobes. The SLF branch projecting to occipital lobe was not detected in our study. The four short association tracts are not well documented in the literature, but were consistently traced as coherent fibers (Fig. 1). **Probabilistic cortical mapping:** Probabilistic cortical maps from different lobes are shown in Fig. 2. The contra-lateral projection is almost symmetric and constituted by the callosal tracts. For ipsi-lateral connectivity, while left frontal lobe is connected to most widely distributed surface areas (Fig. 2a), the mapping is not homogeneous with high probability spots scattered on the rest of the cortical surface. Parietal lobe connections are localized in its surrounding areas (Fig. 2b). Occipital lobe has two remotely connected areas at the temporal pole and lateral prefrontal cortex besides a relatively small area tightly close to itself (Fig. 2c). With a few connections to the adjacent parietal and occipital lobes, the temporal lobe has the majority projection to inferior and lateral frontal lobe (Fig. 2d).

lobes	Fron-L	Par-L	Occ-L	Temp-L
White matter tracts	IFO, UNC, SLF <sub>front</sub> , par-par, CC <sub>front</sub>	SLF <sub>par</sub> , CC <sub>par</sub> , front-par, par-occ, par-temp	IFO, ILF, CC <sub>occ</sub> , par-occ, par-temp	ILF, UNC, CC <sub>temp</sub> , SLF <sub>temp</sub> , par-temp, occ-temp

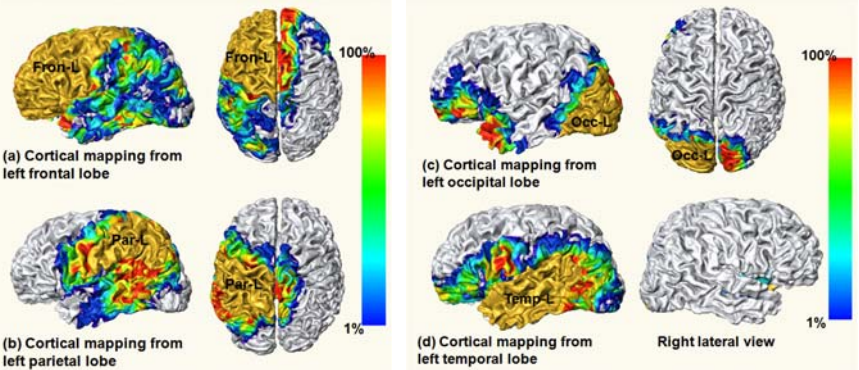
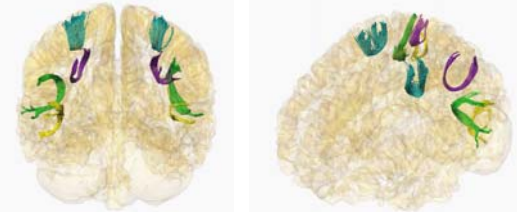


Table 1 (upper left) lists the association tracts connecting the particular cortical lobe to other cortical areas. Fig. 1 (lower left): 3D reconstruction of four short association tracts in its posterior view (left) and oblique view (right) are shown in the images below. Color representations and abbreviations of the fibers are as follows. Blue: fron-par; purple: par-occ; green: fron-temp; yellow: occ-temp. IFO: inferior fronto-occipital tract; ILF/SLF: inferior/superior longitudinal fasciculus; CC: corpus callosum; UNC: uncinate fasciculus. Fig. 2 (right): Probabilistic cortical mapping from left frontal (a), parietal (b), occipital lobe (c) and temporal lobes (d). The cortical lobes from which the association tracts project are painted with brown color. The color bar encodes quantitative values of probabilistic maps on the rest of the cortical surface. The higher the value is, the more likely the cortical region is connected to the specific lobe.

## Discussion

Probabilistic corticocortical connectivity maps from each lobe to other cortical areas are presented. The ultimate goal of this study is to reveal the probabilistic connectivity of defined cortical regions. Cortical gyri can be delineated with detailed cortical parcellation for high resolution connectivity maps. These maps based on structural connectivity can be used as reference for brain functional and disease studies.

**References:** [1] Thottakara, P. et al (2006) *NeuroImage* 29, 868. [2] Hagmann, P. et al (2008) *PLoS Bio.* 6, e159. [3] Oishi, K. et al (2008) *NeuroImage*. [4] Han, X. et al. (2004) *NeuroImage* 23, 997. [5] Mori, S. et al (1999) *Annal. Neurol.* 45, 265. [6] Huang, H. et al. (2004) *Magn. Reson. Med.* 52, 559. [7] Wakana, S. et al. (2004) *Radiology* 230, 77. **Acknowledgement:** NIH/NCRR P41RR015241.