

High resolution ex-vivo diffusion imaging and fiber tracking

T. Benner¹, A. Bakkour², R. Wang¹, and B. C. Dickerson²

¹Radiology, Athinoula A. Martinos Center, Charlestown, MA, United States, ²Gerontology Research Unit, Massachusetts General Hospital, Charlestown, MA, United States

Introduction

The spatial resolution of in-vivo diffusion imaging and fiber tracking in humans is limited by long scan durations and patient motion. Ex-vivo diffusion imaging is the method of choice to achieve spatial resolutions of 1 mm³ or higher. In-vivo diffusion imaging is performed most frequently using 2-dimensional single-shot echo-planar imaging (EPI) because of the relative immunity to subject motion, high SNR and the speed of acquisition. For ex-vivo diffusion imaging, 2-D single-shot EPI is not well suited because of long readout times at high resolution causing susceptibility artifacts as well as limited SNR for thin slices and imprecise slice profiles. 3-dimensional segmented EPI alleviates some of these problems but is still less efficient than e.g. diffusion-weighted steady state free precession (DW-SSFP) imaging [1,2].

The objectives of this study were to test the feasibility of: a) increased spatial resolution compared to previous studies (0.39 mm³ voxel size [3]; 0.5 mm³ voxel size [4]); b) simple tensor based fiber tracking as opposed to probabilistic tractography framework taking into account the analytical expression for the SSFP signal as well as T1 and T2 estimates [4]; c) fiber tracking in gray matter (GM).

Methods

Imaging was done on a 3 T MR scanner (Siemens TIM Trio, Siemens Medical Solutions, Erlangen, Germany) using an in-house designed and constructed 32-channel phased array coil [5]. The brain was obtained from a 51 year old man without known neurologic disorder who died from complications of systemic disease. The post-mortem specimen was fixed in paraformaldehyde using standard procedures. One hemisphere was obtained and used for this study. Diffusion tensor imaging scans were performed in sagittal orientation on one ex-vivo brain hemisphere using a 3D DW-SSFP sequence with the following imaging parameters: TR = 35.9 ms, TE = 30.5 ms, matrix size 352×240×160, 176×120×80 mm³ FoV, 0.125 mm³ voxel size, bandwidth 150 Hz/px, 2 non-diffusion-weighted volumes and 51 diffusion-weighted volumes, resulting in a scan time of 20:20 hours:min. Three such acquisitions were co-registered using FLIRT to correct for B₀ drift and eddy-current distortions [6,7] and then averaged before further processing.

Fiber tracking and visualization were performed using custom-made programs written in C++ using Qt and VTK (<http://www.trackvis.org/>) [8]. The fiber tracking algorithm is based on the Fiber Assignment by Continuous Tracking (FACT) algorithm [9]. For better visualization the following steps were performed: a) short and long fibers were selected separately; short fibers were limited to a length of 2-5 mm within the cortical ribbon, long fibers were limited to a length of 50-160 mm; b) only 10% of all fibers that passed through a 40 mm thick slabs in sagittal orientation were selected.

Results and Conclusion

Figure 1 shows (from top to bottom) a sagittal slice of the mean diffusion-weighted volume, the color coded fractional anisotropy (FA) volume, short fibers and long fibers. A high level of detail can be appreciated in the diffusion-weighted volume and there is good contrast between gray and white matter. The short fibers limited to gray matter are nicely aligned perpendicular to the gray matter ribbon. Figure 1 (bottom) shows the long fibers which are in good agreement with fibers generated from in-vivo 2-D EPI data sets but the ex-vivo data shows more detail.

In summary, spatial resolutions of 0.125 mm³ are feasible with adequate SNR for fiber tracking at 3 T. DW-SSFP data can be used with standard fiber tracking software. Spatial resolution and SNR are high enough to allow fiber tracking in gray matter. Fiber crossings were not resolved due to the tensor model used during processing and fiber tracking.

Acknowledgments

This work was supported in part by the National Institute on Aging (R21 AG029840) and the National Center for Research Resources (P41RR14075).

References

- [1] LeBihan D. Magn Reson Med 1988;7(3):346-351.
- [2] McNab JA, Miller KL. Magn Reson Med. 2008;60(2):405-413.
- [3] McNab JA et al. Proc. 16th ISMRM 2008, 572.
- [4] McNab JA et al. Proc. 16th ISMRM 2008, 3317.
- [5] Wiggins GC, et al. Magn Reson Med. 2006;56(1):216-223.
- [6] Jenkinson M, Smith SM. Medical Image Analysis, 2001;5(2):143-156.
- [7] Jenkinson M et al. NeuroImage, 2002;17(2):825-841.
- [8] Wang R, Wedeen VJ. Proc. 15th ISMRM 2007, 3720.
- [9] Mori S. et al. Ann Neurol, 45(2):265-269, 1999.

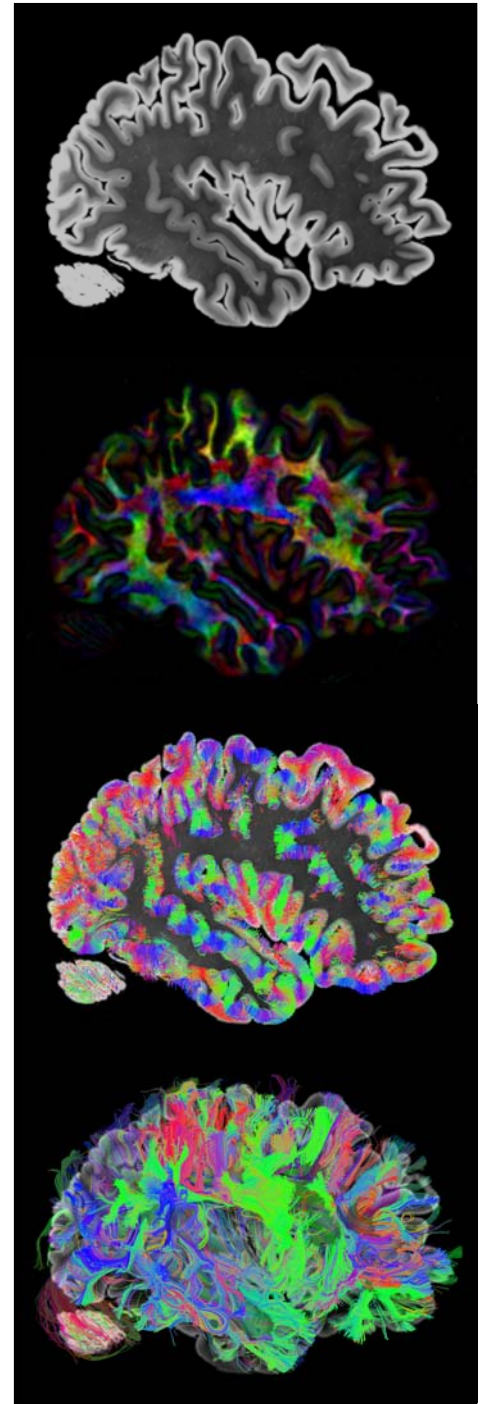


Figure 1: Sagittal view of hemisphere. From top to bottom: mean diffusion-weighted image; color FA image; short fibers only overlaid on DWI image; long fibers only overlaid on DWI image.