

PERFUSION DEFICIT IN SCHIZOPHRENIA AND CORRELATION WITH PSYCHOPATHOLOGICAL SYMPTOMS

J. Uh¹, P. Mihalakos², C. A. Tamminga², and H. Lu¹

¹Advanced Imaging Research Center, University of Texas Southwestern Medical Center, Dallas, Texas, United States, ²Department of Psychiatry, University of Texas Southwestern Medical Center, Dallas, Texas, United States

INTRODUCTION: Basal physiologic parameters such as cerebral blood volume (CBV) and cerebral blood flow (CBF) are important markers for studying the neurodysfunction of schizophrenia (SZ) (1). Previously these parameters were measured mostly by PET or SPECT and fewer MR studies have been completed; however, MR provides advantages in terms of noninvasiveness and higher spatial resolution. Furthermore, the versatility of MRI offers the benefit that the perfusion assessment can be performed in conjunction with other measures such as brain atrophy, water diffusion and neural function within a single scan session. Recently, we have developed a Vascular Space Occupancy (VASO) MRI technique (2) to quantitatively measure CBV utilizing T1 relaxation effect of contrast agent (Gd-DTPA). VASO MRI has several advantages in comparison with other MR methods including that it does not require an arterial input function and it avoids image distortion due to EPI. A disadvantage of MR methods for CBV is that the use of contrast agent may not be feasible for patients with compromised renal function while non-contrast CBF measure does not have this issue. Arterial spin labeling (ASL) technique has been also recently advanced so that CBF of the entire cerebral cortex can now be measured by pseudo continuous ASL (PCASL) (3). In this study, these new MR techniques are used for assessing neurovascular parameters in SZ patients. We first measured CBV maps of a group of SZ volunteers and compared them with normal controls. The CBV result was then confirmed with CBF measured by PCASL MRI. We also investigated the correlation between CBV/CBF and psychopathological symptom assessed by Positive and Negative Syndrome Scale (PANSS) for key regions of interest (ROI).

METHODS: A total of 16 SZ volunteers (SV) (age 43.4±11.7) treated with antipsychotic drugs (APD) and 33 normal volunteers (NV) (age 41.8±12.7) were studied on a 3T system (Philips). PANSS score was obtained for each SV according to the protocol of Kay et al. (4) within one week of the MR scans. VASO scan was performed on 10 SV (age 40.6±13.5) and 12 NV (age 40.7±14.0) with 34 coronal slices (thickness 5mm, resolution 1.5x1.5mm²) to cover the entire brain (TE/TR=3.4ms/6000ms, duration 2.5 min). SVs with glomerular filtration rate (GFR) less than 60 ml/min per 1.73m² body surface (5) were excluded from the VASO scan. PCASL scan was performed on 11 SV (age 41.8±11.6) and 22 NV (age 42.9±12.3). We used 17 axial slices (thickness 7 mm, resolution 3x3mm²) for PCASL to cover the entire cerebral cortex (TR/TE=4000/14ms, 30 control/label images, duration 4 min). T1w MPRAGE (1x1x1mm³) was also acquired for structural assessment and image registration.

The CBV maps were calculated from pre- and post-contrast VASO images (2). CBF maps were obtained from the PCASL data using a model proposed by Alsop and Detre (6). Inter-subject variations in global CBV and CBF were minimized by scaling the maps to whole brain (CBV) or entire cerebral cortex (CBF) values, yielding relative CBV and CBF maps. These individual brain images were spatially normalized into MNI space using the T1w image. It has been reported that SZ is often accompanied by brain atrophy (7), which needs to be corrected in order to avoid partial volume effects on CBV or CBF maps. We used an elastic registration software, HAMMER (8), for the spatial normalization. The HAMMER algorithm also creates a deformation matrix containing atrophy information which can be used for atrophy mapping. Figure 1 shows the atrophy mapping of the 16 SV compared with the 33 NV. It is clearly seen that there is significant atrophy particularly at medial frontal regions, consistent with findings in the literature (7). SV and NV groups were compared by voxel-wise analysis and ROI analysis. The ROIs studied include frontal, temporal, parietal, occipital and limbic lobes, and subregions of frontal and limbic lobes.

RESULTS and DISCUSSION: A voxel-wise analysis of CBV data in SV vs NV shows an extensive perfusion deficit in SV in the anterior pole of the frontal lobe (Fig. 2, bottom left). The ROI analysis also shows a significant deficit in superior gyrus (p=0.01) and medial/orbital surfaces (p=0.05) of the frontal lobe, with CBV reduction of 7.8% and 5.2%, respectively. This CBV deficit is consistent with many previous studies reporting prefrontal cortex dysfunction in SZ (9). Moreover, within the patient group, there was a negative correlation (Fig. 3, top left) between the average CBV of the frontal lobe and the PANSS scores indicating that higher schizophrenia symptoms are correlated with reduced CBV values. On the other hand, in hippocampus/parahippocampal gyrus there is a positive correlation between CBV and PANSS (Fig. 3, top right). The positive correlation implies that SZ patients with a substantial symptom load tend to have increased CBV in these ROIs at rest. This hyperperfusion of the hippocampus in SV has been previously reported using PET and supports the hypothesis that NMDA-sensitive glutamate receptor may be abnormal (ie, upregulated) in the SZ hippocampus (10). The CBF results are highly consistent with the CBV data. The group analysis shows CBF deficit in frontal lobe (Fig. 2, bottom right), and ROI analysis shows a CBF reduction by 11.0% at medial/orbital surfaces of frontal lobe (p=0.023). The significant negative correlation in frontal lobe and positive correlation in hippocampus of CBF and PANSS were also observed (Fig. 3 bottom row). A discrepancy between CBV and CBF was found in visual cortex, where a significant CBF reduction by 10.1% (p=0.002) was observed (Fig. 2, bottom right), for which further investigation is needed.

In summary, this work demonstrates that patients with SZ manifest altered perfusion and the perfusion measures are correlated with psychopathological symptoms. CBV and CBF derived from MR measures find parallel results in the characterization of SZ patients as those performed by PET or SPECT. An advantage of the MRI method is that these techniques can be performed in the same imaging session as other structural/functional/neurochemical MR assessments.

REFERENCES: 1) Lahti et al. *Neuropsychopharmacology*, 31:221, 2006; 2) Lu et al. *MRM*, 54:1403, 2005; 3) Wu et al. *MRM*, 58:1020, 2007; 4) Kay et al. *Schizophr Bull*, 13:261, 1984; 5) Rule et al. *Ann Intern Med*, 141:929, 2004; 6) Alsop and Detre *J Cereb Blood Flow Metab*, 16:1236, 1996; 7) Meda et al. *Schizophr Res*, 101:95, 2008; 8) Shen and Davatzikos *IEEE Trans Med Imag*, 21:1421, 2002; 9) Andreasen et al. *Lancet*, 349:1730, 1997; 10) Medoff et al. *Hippocampus*, 11:543, 2001.

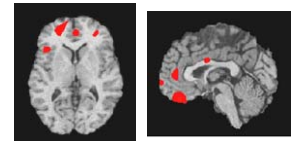


Fig. 1: Medial frontal regions showing increased atrophy in SV compared to NV (2 sample t test, uncorr p=0.01, k=200).

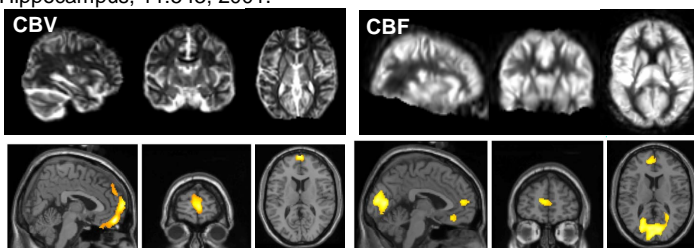


Fig. 2: Averaged CBV and CBF maps of SV (top row) and regions showing CBV/CBF deficits of SV compared to NV (bottom row, 2 sample t test, uncorr p=0.01, k=200).

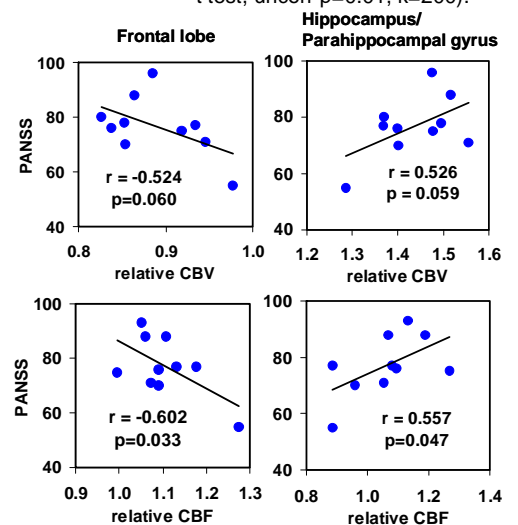


Fig. 3: Correlation between PANSS score and CBV/CBF of frontal lobe (left) and Hippocampus/Parahippocampal gyrus (right).