

Systematic Investigation of Volume Changes Induced by Prenatal Alcohol Exposure in Cortical and Sub-cortical Regions

X. Chen¹, M. E. Lynch², X. Hu¹, and C. D. Coles²

¹Biomedical Imaging Technology Center, Emory University, Atlanta, GA, United States, ²Department of Psychiatry and Behavioral Sciences, Emory University, Atlanta, GA, United States

Introduction

Brain structural and behavioral changes in individuals exposed prenatally to alcohol have been reported previously¹⁻². However, no systematic investigation has been performed by means of segmenting the cerebral cortex and the sub-cortical structures into various regions of interest. Because these cortical and sub-cortical regions are usually well organized and involved in certain cognitive functions, study with this approach will help us to systematically understand the prenatal alcohol exposure (PAE) related brain structural changes, and provide a basis for understanding the behavioral alterations underpinned by these structural changes.

Methods

From a longitudinal cohort, three participant groups (control: 12 male and 14 female, dysmorphic: 14 male and 16 female, non-dysmorphic: 10 male and 26 female) which were matched in ethnicity, age and education, participated in this study. The two PAE groups (dysmorphic and non-dysmorphic) were differentiated by their facial dysmorphia ratings. For each participant, T₁-weighted images were obtained on a 3.0 Tesla Siemens Magnetom TRIO scanner with an MPRAGE sequence (TR = 2600 ms, TE = 3.02 ms, Flip Angle = 8°, voxel size = 1×1×1 mm³). FreeSurfer software was used to segment sub-cortical structures, grey and white matters, and cortical regions. Volumetric data for the cortical and sub-cortical regions of interest were also calculated with FreeSurfer³. GLM in SPSS 15.0 was used for statistical analysis.

Results

Cortical regions exhibiting reduced volume by PAE are shown in Figure 1A. At a glance, both hemispheres were widely affected. Sub-cortical grey matter regions which were affected by PAE are shown in Figure 1B. These regions included the caudate, putamen, pallidum, thalamus and amygdala in both hemispheres, the right hippocampus, and the left accumbens area. Gross volumes of the left and the right cerebral and cerebellum cortices were also reduced by PAE. For the corpus callosum, its posterior, mid-posterior and anterior portions demonstrated the PAE effect (Figure 1C).

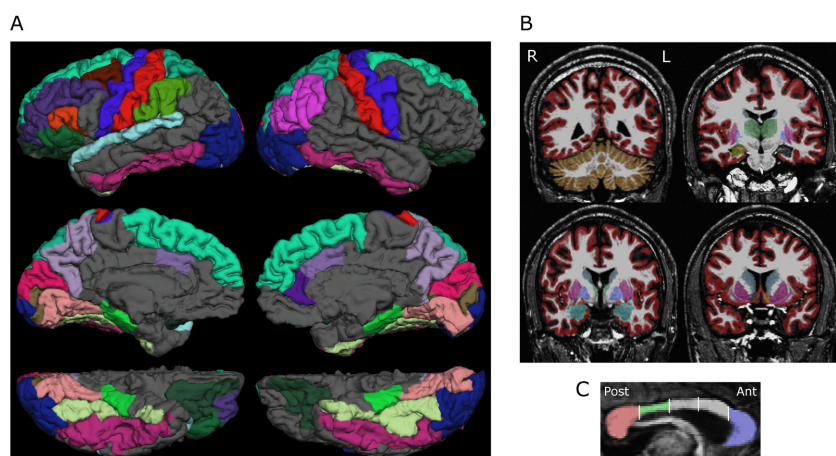


Figure 1. Cortical (A) and sub-cortical (B) regions, portions of corpus callosum (C) exhibiting reduced volume by PAE. R: right hemisphere, L: left hemisphere. Ant: anterior, Post: posterior.

regions in the right hemisphere; in contrast, the right hippocampus showed larger PAE effect than the left hippocampus.

Discussion and Conclusion

Details about the cortical parcellation and sub-cortical segmentation enable us to achieve a comprehensive understanding of the PAE-related brain structural changes. For examples, almost all components of cortical visual system, attention network, motor system, executive control and working memory system, were impacted in the dysmorphic participants. These results, along with the behavioral evidence, suggest that most brain structures can be affected by PAE. In addition, our data about the non-dysmorphic participants support that alcohol is a teratogen that may produce a spectrum of brain structural and functional deficits: from the mild through the moderate to the severe. Moreover, the gender and the interhemispheric difference in PAE effect may shed some light on the special teratogenic mechanism of alcohol on human brain.

Acknowledgements This work is supported in part by the NIH (R01 AA014373).

References

1. Niccols, A. Brain Cogn, 2007, 65(1): 135-142.
2. Riley, E.P. and McGee, C.L. Exp Biol Med (Maywood), 2005, 230(6): 357-365.
3. <http://surfer.nmr.mgh.harvard.edu/fswiki>.