

Diffusion tensor imaging tractography of the corticospinosensory pathway in painless diabetic neuropathy

M. E. Hutton^{1,2}, D. Selvarajah¹, S. Tesfaye¹, and I. D. Wilkinson^{1,2}

¹Sheffield Teaching Hospitals NHS Trust, Sheffield, South Yorkshire, United Kingdom, ²Academic Radiology, University of Sheffield, Sheffield, South Yorkshire, United Kingdom

Introduction

Diffusion Tensor magnetic resonance imaging (DTI-MRI) is a non-invasive imaging technique that can be used to measure the anisotropy in parenchymal water diffusion *in-vivo*. This information can be used to reconstruct models of the complex white matter tracts (fiber tractography) in the CNS which may then be used to detect differences between subject groups. Recent imaging studies^{1, 2} have indicated spinal and intracranial involvement in subjects with 'peripheral' diabetic neuropathy (DN) in addition to the well-documented peripheral nerve and vascular abnormalities. DT-MRI tractography studies can help us understand the changes that may be taking place in the spinal-corticospinosensory pathways in subjects with DN. In this study we make a quantitative comparison between the fiber tractography results for the corticospinosensory pathways in a healthy subject group and a DN group.

Methods

A total of 8 healthy volunteers (HV; mean age 36±10) and 6 type I diabetic subjects with painless DN (mean age 58±11) were imaged at high-field and DTI-MRI tractography performed. The DTI data was obtained at 3T (Achieva 3.0T, Philips Medical Systems, Best, Netherlands) with the following imaging parameters: Single-shot echo-planar imaging DTI, diffusion directions = 32, b-value = 1000s/mm², resolution = 1.75×1.75×2mm, 70 axial slices positioned along the anterior commissure-posterior commissure (AC-PC) covering the entire cerebrum and cerebellum. Tractography was performed using MedINRIA (www-sop.inria.fr; FA threshold = 150, smoothness = 20, minimum length = 30, sampling = 2), which uses an advection based propagation technique³. Pre-processing using FSL⁴ was used to extract the brain and to perform eddy-current corrections. ROIs were placed in the brainstem above the level of the crossing pontine fibers and in the right and left primary somatosensory cortex for all subjects. The total number of fibers connecting the brainstem ROI and the somatosensory cortex ROIs and the mean fractional anisotropy (FA), apparent diffusion coefficient (ADC) and the eigenvectors (λ_1 , λ_2 , λ_3) along the connecting fibers were compared for the HV and DN groups. Intra-group differences were assessed using the hemisphere with the greatest number of fibers connecting the ROIs.

Results and Discussion

A representative model of the extracted pathway is shown in Fig. 1. Results for the number of fibers connecting the two ROIs, and the FA, ADC and eigenvectors are shown in Table 1. There are more fibers connecting the two ROIs for the HV group though the differences between the HV and DN groups are statistically insignificant (unpaired t-test; t=0.74, df=12, p=0.48). There are also no significant differences between the FA, ADC and eigenvectors for the groups.

Fig.1. Example coronal view showing connectivity between brainstem and somatosensory cortex for a HV

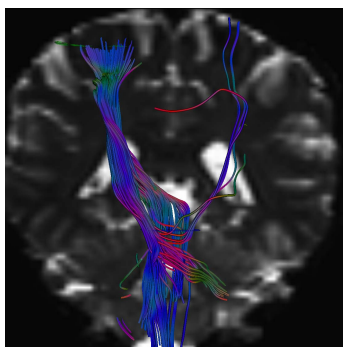


Table 1. Tractography results

	Number of fibers		FA		ADC (mm ² s ⁻¹)		λ_1 (mm ²)		λ_2 (mm ²)		λ_3 (mm ²)	
	HV	DN	HV	DN	HV	DN	HV	DN	HV	DN	HV	DN
Mean	350	297	0.49	0.5	2.39	2.41	1.22	1.24	0.71	0.71	0.46	0.46
SD	134	133	0.04	0.03	0.23	0.13	0.09	0.06	0.07	0.04	0.07	0.04

These preliminary data support previous work^{1, 2} which suggests that there are abnormalities in the spino-corticospinosensory pathways within the brains of individuals with DN. The FA, ADC and eigenvectors appear unchanged in the DN group, but the number of axonal fiber tracts within the corticospinosensory pathways is reduced, although not statistically significant in this small sample size. The current results are inconclusive and therefore additional HV and painless DN data is being acquired. Data is also being acquired to determine whether similar abnormalities are present in diabetics with no DN and whether differences can be observed between subjects with painful and painless DN.

[1] Eaton S E M, *et al.*, Spinal cord atrophy in diabetic peripheral neuropathy, Lancet 2001, 358:35-36

[2] Selvarajah D, *et al.*, Early involvement of the spinal cord in 'peripheral' diabetic neuropathy, Proc Intl Soc Mag Reson Med 11:1532, Kyoto, Japan, 15th-21st May, 2004

[3] Weinstein D M, *et al.*, Tensorlines: Advection-diffusion based propagation through diffusion tensor fields, Proceedings on the conference on Visualization 1999, 249-253

[4] Smith S M, *et al.*, Advances in functional and structural MR image analysis and implementation as FSL, NeuroImage 2004, 23(S1):208-219