

# Diffusion Tensor Imaging Abnormalities in Children with Cerebellar Mutism after Posterior Fossa Tumor Resection

N. S. Phillips<sup>1</sup>, E. Morris<sup>2</sup>, F. H. Laningham<sup>3</sup>, A. Gajjar<sup>4</sup>, and R. J. Ogg<sup>1</sup>

<sup>1</sup>Translational Imaging, St. Jude Children's Research Hospital, Memphis, Tennessee, United States, <sup>2</sup>Neurology, St. Jude Children's Research Hospital, <sup>3</sup>Diagnostic Radiology, Children's Hospital Central California, <sup>4</sup>Neuro Oncology, St. Jude Children's Research Hospital

**Background:** Cerebellar Mutism (CM) is a post-operative complication characterized by cerebellar dysfunction, oromotor/oculomotor apraxia, apathy, and mutism. Interestingly, symptom onset is usually 24-48 hours after an otherwise unremarkable post-operative period. Recovery is variable, but, significant long-term cognitive, behavioral, and/or motor deficits are frequently recognized in these children.<sup>1-4</sup> The disrupted physiology underlying these striking neurobehavioral deficits is not well delineated.

**Purpose:** Using DTI, identify disrupted neuroanatomical pathways associated with CM features that potentially predict development of CM and identify patterns of injury associated with CM.

**Methods:** After surgical resection, 62 children with posterior fossa embryonal tumors were enrolled on an IRB approved institutional protocol. 10 patients were diagnosed with CM and were compared to 13 matched patients (age, MRI timing) without CM. Diffusion weighted images were acquired with a single-shot, spin-echo, echo-planar acquisition sequence with eddy current balanced diffusion weighting gradient pulses to reduce distortion (6 encoding directions with  $b = 1000 \text{ sec/mm}^2$ ; echo time (TE)/repetition time (TR) = 127 msec/10 sec; matrix =  $128 \times 128$  on  $230 \text{ mm} \times 230 \text{ mm}$  field of view (FOV); slices 3 mm without gap resulting in voxels of  $1.8 \times 1.8 \times 3 \text{ mm}$ ). Four measurements of the diffusion data were averaged after realignment and reslicing (SPM2, <http://www.fil.ion.ucl.ac>). The tract-based spatial statistics (TBSS) tool in FSL was used to identify tract-based differences in FA values between the CM and control patients. (FMRIB Centre, University of Oxford, Oxford, United Kingdom).

**Results:** Three white matter regions had significantly reduced FA in patients with PFS: 1) bilateral superior cerebellar peduncles, 2) bilateral fornices (column), and 3) area subserving right supramarginal/angular gyrus.

**Conclusions:** The most notable and novel finding of this study was the observation that FA values among patients with CMS are significantly decreased within both SCP's, as well as, both columns of the fornices, and in the region of the right posterior parietal lobe. Reduced integrity of white matter bundles within the SCP further implicates DTC tract involvement in CMS. The remote supratentorial abnormalities are provocative. Although these findings require further confirmation, involvement of fornices and right temporoparietal head region on DTI are interesting findings and might underlie the observed neurobehavioral aspects of PFS.

## References:

1. Doxey D, et al., *Pediatr Neurosurg* 31:131-6, 1999
2. Huber JF, et al., *Childs Nerv Syst* 22:132-8, 2006
3. Steinbok P, et al., *Pediatr Neurosurg* 39:179-83, 2003
4. Steinlin M, et al., *Brain* 126:1998-2008, 2003

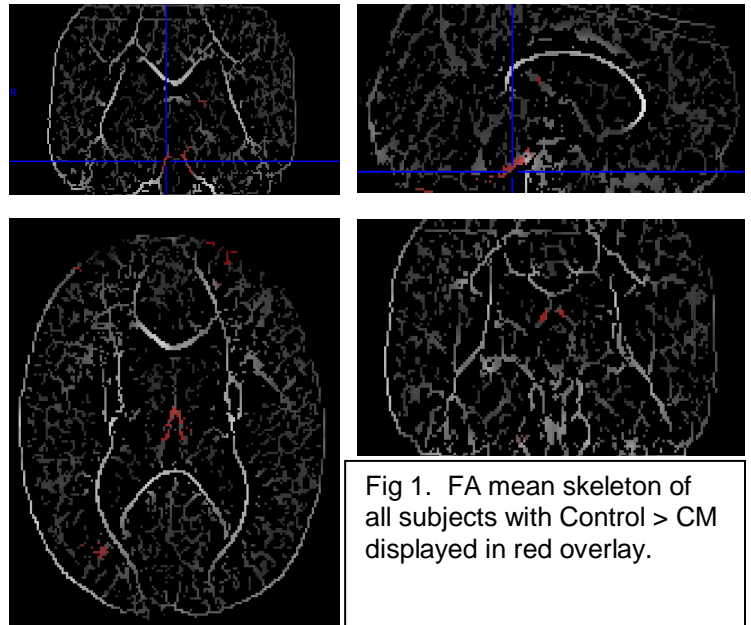


Fig 1. FA mean skeleton of all subjects with Control > CM displayed in red overlay.