

# Perioperative Changes in Diffusion Tensor Imaging of White Matter in Patients with Brain Tumors

K. K. Peck<sup>1</sup>, T. Sierra<sup>2</sup>, Z. Zhigang<sup>3</sup>, R. Baser<sup>3</sup>, and R. Young<sup>3</sup>

<sup>1</sup>Memorial Sloan-Kettering Cancer Center, New York, New York, United States, <sup>2</sup>Mount Sinai Medical School, New York, <sup>3</sup>Memorial Sloan-Kettering Cancer Center, New York, United States

## Introduction

Diffusion tensor imaging (DTI) is a relatively new MRI technique that allows the unprecedented in vivo evaluation of white matter tracts. DTI is proving to be useful in a range of applications, such as planning brain tumor surgery, glioma grading and image-modulated radiation therapy (1, 2). Despite the growing role of DTI, the effects of surgery and associated perioperative medications (steroids, anesthesia and antibiotics) on DTI metrics are not well understood. The peritumoral region is an important area that may harbor infiltrating tumor cells in gliomas. The peritumoral region is also susceptible to mechanical and ischemic injury during surgery. We hypothesize that the peritumoral region is susceptible to DTI-measurable changes after surgery.

## Subjects

Preoperative (preop) and postoperative (postop) MRIs with DTI were performed in seventeen patients (10 men, 7 women; median age 51 years) treated for brain tumors. The group included 8 gliomas, 7 metastases, and 2 radiation necrosis cases. All patients had postoperative scans obtained within 24 hours of surgery. Diagnosis and grading of tumors was confirmed by histopathology using surgically resected tissue.

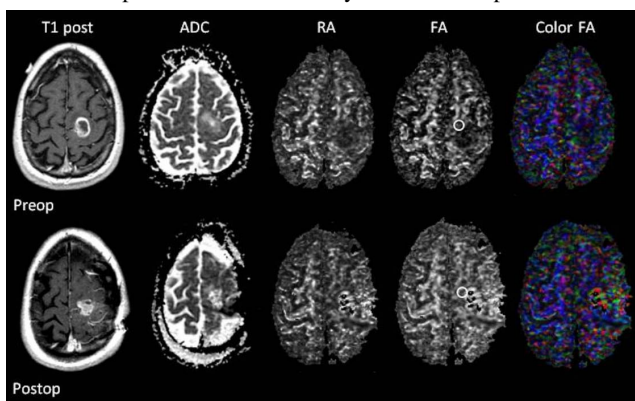
## Method and Data Analysis

The same DTI protocol was applied at the preop and postop MRIs using a 1.5T GE magnet: a spin-echo echo-planar sequence was acquired in 25 directions with TR/TE=12 sec/100 msec, matrix 128x128, Slice Thickness=3 mm, b-value 1000 sec/mm<sup>2</sup>. Total of 40-45 axial slices were obtained to cover the entire brain. Data analysis was performed using DTI Studio (3), and fractional anisotropy (FA), relative anisotropy (RA) and apparent diffusion coefficient (ADC) maps were constructed. Regions-of-interest (ROIs) were drawn in corresponding areas on the preop and postop scans: tumor, peritumoral area, normal-appearing white matter (NAWM) immediately adjacent to the tumor, NAWM on a standard slice at the level of the internal capsule, thalamus, corpus callosum, posterior limb of the internal capsule, brachium pontis, and corticospinal tract in the pons. The structures were analyzed separately for genu/splenium and left/right sides when appropriate, yielding a total of 13 brain areas examined. Global peak FA and ADC values were generated using AFNI (4). Statistical analysis was performed using both exact and asymptotic Wilcoxon signed-rank tests. Correlations between DTI metrics and glioma grade were examined using Kruskal-Wallis tests, repeated measures analysis of variance, and multivariate analysis of variance.

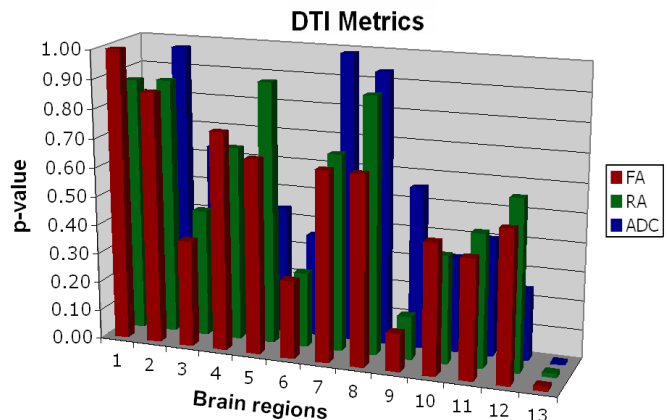
## Results

The peritumoral DTI metrics showed a significant change between the preop and postop scans, with increasing FA and RA and decreasing ADC ( $p < 0.02$ ). (Fig 1) No difference was found between the glioma and nonglioma groups. No correlation was observed between the peritumoral metrics and glioma grade. The other 12 regions analyzed did not show any significant change after surgery ( $p > 0.13$ ) (Fig 2). The global histogram measurements also did not demonstrate any significant change ( $p > 0.31$ ).

**Fig 1.** Preop and postop images in a glioblastoma patient with ROIs in the peritumoral abnormality on the FA maps.



**Fig 2.** Bar Graph of p-values



[Note: (1) tumor, (2) NAWM immediately surrounding the tumor, (3) thalamus, (4) left posterior limb of the internal capsule, (5) right posterior limb of the internal capsule, (6) genu of corpus callosum, (7) splenium of corpus callosum, (8) NAWM on a standard slice, (9) left brachium pontis, (10) right brachium pontis, (11) left corticospinal tract, (12) right corticospinal tract, and (13) peritumoral area]

## Conclusion

DTI demonstrates changes in the peritumoral region immediately after surgery. The exact etiology of these changes remains uncertain. These changes occur in both glioma and nonglioma patients, although only the peritumoral region of gliomas reflects both edema and infiltrating tumor cells. For gliomas, researchers have proposed using advanced MRI such as DTI to taper the peritumoral margins from the standard 2-3 margin, in order to construct individualized radiation therapy plans that would spare more normal brain and allow modest dose escalations. The implications of DTI on such individualized plans and the optimal timing to perform the planning MRIs after surgery are not well understood. Further research is necessary to better characterize the DTI changes and potential therapeutic implications.

**References** 1. Auer D. et al., International. Congress. Series, 1247:153-163 (2002), 2. Jena R. et al., Clinical Oncology, 17:581-590 (2005), 3. Jiang H et al, Comp Methods Program Biomed, 81:106-116 (2006) 4. Cox RW, Comp Biomed Res 29:162-173 (1996)