

Morphological changes in brain during new language acquisition: A VBM study

S. Modi¹, M. Bhattacharya¹, P. Kumar¹, and S. Khushu¹

¹NMR Research Centre, Institute of Nuclear Medicine and Allied Sciences, Delhi, Delhi, India

Introduction:

Voxel Based Morphometric (VBM) studies have been carried out in musicians, taxi drivers, bilinguals [1, 2, 3] etc., to see the effect of training on the morphometry of the human brain. Those studies have given evidence of the 'neuroplasticity' that is the lifelong ability of the brain to reorganize neural pathways, based on new experiences and knowledge. Japanese is the member of the Japanese language family which uses both ideograms and phonograms as their characters as against the Indo-European family of languages that use phonograms as characters. As against the major Indo-European languages, Japanese characters are generally written vertically from top to bottom, and lines are written from right to left. Besides, there are other significant differences in the vowels, consonants and the grammar rules. It is always easier to learn languages of the same language family because of the similar grammar and vocabulary rules. In order to find the changes in brain morphometry, on acquisition of a language of a different family, optimised Voxel Based Morphometry (VBM) was carried out in Indian students learning Japanese.

Materials & Methods:

Seventeen subjects having a 2 years experience of learning Japanese (20-30 years, 9 males, 8 female, with a prior knowledge of Hindi, English and Punjabi) and Twenty two controls (20-30 years, 11 male, 11 female, with knowledge of Hindi, English and Punjabi) were recruited for the study. None of the subjects chosen for the study had any clinical evidences of stroke, head injury, cardiovascular diseases, history of drug dependence, neurological or psychiatric disorder nor did they have any cortical infarctions on the T2-weighted MR images. The MRI scans were acquired using 1.5 Tesla whole-body MRI system (Siemens Magnetom Vision, Erlangen, Germany) with a circularly polarized head coil and 25 mT/m actively shielded gradient system. T₁ weighted 3D-MPRAGE sequence with 160 thin slices was performed in the sagittal plane, FOV = 256x256 mm². Pre-processing and post-processing was performed using SPM2 software in MATLAB environment. Talairach-Daemon Client was used for estimation of Brodmann Areas.

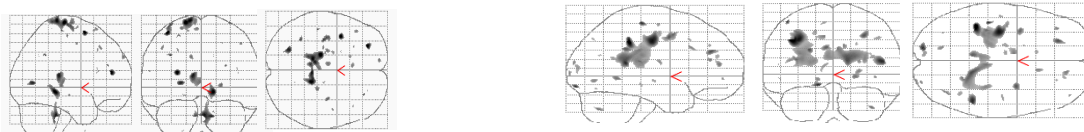
Results & Discussion:

The normalized, segmented, smoothed and modulated data sets were assessed using the 'ANalysis Of VAriance (ANOVA)', thresholded at $p \leq 0.001$ uncorrected, to find the differences in the brain tissue composition of the two subject groups.

Significant increase in gray matter volume was obtained in middle and superior frontal gyrus (BA 6, 8, 9), precentral gyrus (BA 6); inferior parietal lobule (BA 40); thalamus; parahippocampal gyrus and posterior cingulate (BA 30) in the limbic lobe in the Japanese learning group as compared to controls. The Supplementary Motor Area (BA 6) has been implicated in the automatic internal generation of words during single word processing [4]. BA 9 is associated with working memory, sustained attention, episodic memory encoding and retrieval components. Inferior parietal region is believed to be involved in the short term storage and processing of phonological representations which form a part of reading comprehension alongwith a possible involvement in recoding visual input into auditory form. Parahippocampal gyrus plays an important role in the formation and retrieval of topographical memory. It might also play a role in learning Japanese characters.

Similarly, an increase in the white matter was found in the middle and medial frontal gyrus; inferior parietal lobule, post-central gyrus; superior temporal gyrus; middle occipital gyrus, lingual gyrus, cuneus in the occipital lobe; insula; cingulate gyrus in the limbic lobe; and tuber in the Japanese learning group as compared to controls. Cingulate gyrus has been implicated in attentional and 'central executive' processing tasks and has been found to be activated for second language (other than native) processing [5]. The area for phonological recognition is mostly in the superior temporal gyrus, and adjacent portions of the temporal lobe play a large role in managing lexical and semantic information. Visual cortex has been found to be related to the length or visual complexity of the stimulus while lingual gyrus has been associated with both reading and object processing relative to visual controls.

Thus, individuals, learning Japanese show an increase in gray and white matter volume in regions that play an important role in language processing and learning.



'ANOVA' showing regions of (a) increased **GM volume** in Japanese learning group as compared to controls
(b) increased **WM volume** in Japanese learning group as compared to controls

Conclusion:

Our findings suggest that neural plasticity in humans may lead to use-dependent regional growth and structural adaptation in cerebral gray-white matter in response to new learning skills.

References:

1. The Journal of Neuroscience, 2003; 23(27):9240 –9245.
2. Hippocampus. 2003;13(2):250-9
3. Nature. 2004;431(7010):757
4. Ellis A W and Young A W. Human Cognitive Neuropsychology. Hove, Erlbaum, UK (1988)
5. Neuroreport, 8: 3809 (1997).