

fMRI of patients with acute and chronic low back pain

H. A. Sharma¹, G. Rajshri², E. Wee³, S. Marner⁴, and W. Olivero⁵

¹Biomedical Imaging Center, University of Illinois at Urbana-Champaign, Urbana, IL, United States, ²Medical College, University of Illinois, Urbana, IL, United States,

³University of Illinois at Urbana-Champaign, United States, ⁴Carle Clinic, ⁵Neurosurgery, Carle Foundation Hospital, Urbana, IL, United States

Introduction: fMRI studies have made significant contributions to the understanding of how the brain processes pain. Studying patients with acute pain has been difficult because of the difficulty in altering the patient's painful experience during fMRI and motion artifacts. Back pain with radiating leg pain resulting from a herniated lumbar disc is a common clinical pain syndrome. The severity of the pain can be altered by relatively simple maneuvers such as straight leg raising, muscle tensing etc. We found that the straight leg raise maneuvering was the most reliable method for activating the pain matrix in patients with back and leg pain. How the brain processes acute vs chronic pain remains uncertain. Also, the differences in fMRI in patients with chronic vs acute pain has not been well characterized.

We elected to study patients with chronic back pain and acute back pain from a herniated disc in the lumbar areas using the above methods of attempting to alter the pain perception to determine if we could reliably differentiate between acute and chronic pain conditions and to determine which regions of the brain are more active in the acute vs chronic pain conditions.

Methods: Chronic and acute back pain patients were imaged in a 3T Siemens Allegra scanner using a single channel quadrature coil.

Subjects with no backpain history were used as controls. The subjects signed a written consent form approved by the local IRB. A Block design was used for fMRI stimulus design. The blocks consisted of 20s legraise and 20s rest. A T2 *-weighted EPI sequence (TR/TE/FA = 2000ms/30ms/77°) was used to acquire whole brain volumes (32 slices) at a voxel dimension of 3.8x3.8x4. High resolution T1-weighted anatomical images were acquired with an MPrage sequence.

Analysis: fMRI data were analyzed using Brainvoyager QX. The standard sequence of preprocessing steps were performed for the fMRI data, including slice scan time correction, high pass filtering and spatial smoothing. 3D head motion correction was performed to detect and correct for small head movements. Estimated translation and rotation parameters were inspected. The anatomical data was corrected for spatial intensity inhomogeneities. The data was then resampled to 1 mm resolution and transformed into ACPC and Talairach standard space. The fMRI data was co-registered with the subject's 3D anatomical data and then normalized so that the analysis could be done in the talairach space. For each subject block data, a Brainvoyager protocol file was derived representing the onset and duration of the tasks for the different conditions. In order to account for hemodynamic delay and dispersion, each of the predictors was derived by convolution of an appropriate boxcar waveform with a doublegamma hemodynamic response function. Using hypothesis driven, voxelwise standard analyses, we tested for overall task related effects in different groups..

Results: Figure 1,2 and 3 summarize the main results of the group analysis. Significant effect of pain from right leg raise was seen in the thalamus and the amygdala. Figure 1 show no activations in the pain regions of the brain for control group. Figures 2 and 3 show the activations in the motor cortex for straight legraise and activations in the thalamus and the amygdale regions respectively for pain.

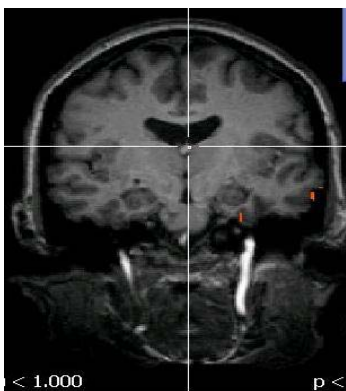


Fig 1. Activation for no pain

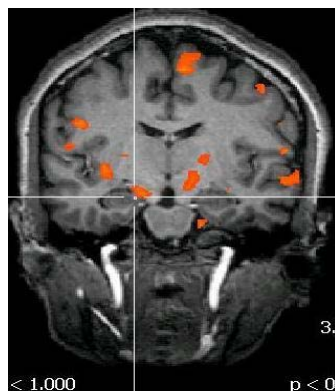


Fig 2. Activation for chronic pain

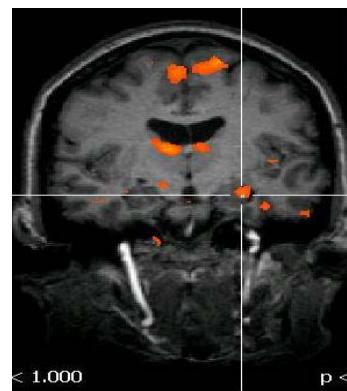


Fig 3. Activation for acute pain

Discussion: Chronic pain is a common medical problem affecting as much as 15% of the adult population. Although the treatment for acute pain is relatively successful chronic pain remains poorly treated primarily because of a lack of understanding of the primary pathophysiology. We previously presented data demonstrating the use of fMRI in imaging patients with acute low back pain and radiculopathy. Here we present some preliminary data comparing patients with lumbar pain of an acute nature (lasting less than 3 months) and compare them to patients with more chronic pain (lasting at least 1 year) and normal controls. We found more robust activation in the patients with acute pain in the S1, bilateral thalami, contralateral amygdale and cingulate gyrus as compared to patients with chronic pain and controls. The change in the level of pain on a 10 point visual analog scale were similar in both pain groups. Patients with chronic pain seemed to have more diffused brain activations than those with acute pain.

References: Apkarian, A.V., Bushnell, M.C., Treede, R.D., Zubieta, J.K., 2005. Human brain mechanisms of pain perception and regulation in health and disease. *Eur J Pain* 9, 463-484. Jeanmonod, D., Magnin, M., Morel, A., 1993. Thalamus and neurogenic pain: physiological, anatomical and clinical data. *Neuroreport* 4, 475-478. Functional magnetic resonance imaging, Huettel Scott A., Song Allen W.