

# Cerebral perfusion in patients with major depression - a Pseudo Continuous Arterial Spin Labelling MRI study

H. Järnum<sup>1</sup>, E. G. Steffensen<sup>1</sup>, L. Knutsson<sup>2</sup>, E. T. Fründ<sup>1,3</sup>, C. W. Simonsen<sup>1</sup>, I. S. Thomsen<sup>4</sup>, A. Shankaranarayanan<sup>5</sup>, D. C. Alsop<sup>6</sup>, F. T. Jensen<sup>1</sup>, P. M. Jørgensen<sup>1</sup>, and E-M. Larsson<sup>1</sup>

<sup>1</sup>Department of Radiology, Aalborg Hospital/Århus University Hospital, Aalborg, Denmark, <sup>2</sup>Department of Medical Radiation Physics, Lund University Hospital, Sweden, <sup>3</sup>GE Healthcare - Applied Science Laboratory Europe, <sup>4</sup>Aalborg Psychiatric Hospital/Århus University Hospital, Aalborg, Denmark, <sup>5</sup>GE Healthcare, United States, <sup>6</sup>Beth Israel Deaconess Medical Center and Harvard Medical School, United States

**Introduction:** Major depression is the most common psychiatric disorder. In the United States, one in six people experience a depressive episode during their lifetime. Although the clinical symptoms are well described in the literature, less is known about the brain pathology accompanying the disease. Results concerning cerebral perfusion are divergent, indicating a need for further evaluation of cerebral blood flow (CBF) among these patients.

**Purpose:** To evaluate cerebral perfusion obtained in patients with major depression compared with healthy controls using 3D Pseudo Continuous Arterial Spin Labelling (PC ASL).

**Methods:** *Patients:* Prospective study of outpatients with major depression (planned 45 patients). Inclusion criteria:  $\geq 18$  on the Hamilton Rating Scale for Depression (HAM-D) or  $\geq 9$  on the HAM-D subscale. Use of SSRI or other anti-depressant medication was noted. After a baseline MR scan a follow-up scan was obtained when HAM-D was  $\leq 7$  (considered healthy) or 6 months after the first scan. *Control group:* 29 healthy volunteers 15 men, mean age 45 years (age range 24-63 years) and 14 women, mean age 38 years (age range 22-62 years). Volunteers were scanned twice with 30 min. intervals. No caffeine or nicotine was permitted in the break between two measurements. *MRI protocol:* MRI was performed on a 3T system (Signa HDx, R14M5, GE Healthcare). Axial 3D Pseudo Continuous (PC) FSE ASL with spiral acquisition: 512 sampling points on 8 spirals, TE/TR= 1.9/ 9.2ms, delay time 1.5s, FOV 24cm, recon. matrix 128x128, slice thickness 5mm, 32-34 slices. Scan time approx. 5min. A CBF dataset reconstructed on the scanner (host) with software provided by GE Healthcare was used for analysis. *Perfusion analysis:* The perfusion evaluation was done with an in-house developed analysis software using regions of interest (ROIs) (fig 1), representing cerebellum, frontal, parietal, occipital and temporal lobes. *Statistics:* Repeatability was analyzed according to Bland and Altman for the mean CBF values of the two measurements. The analysis of difference in perfusion between controls and patients was done by ANOVA, hereby assuming perfusion values to be normally distributed. The study was approved by the local ethics committee.

**Results:** So far 15 patients have undergone their first scan, 6 men mean age 39 years (age range 33-48 years) and 9 women, mean age 36 years (age range 23-61 years), with a mean HAM-D score of 21. The repeatability coefficient for whole brain perfusion in the healthy controls was 5.7 ml/100g/min. Since a gender difference in cerebral perfusion was found in the control group (fig. 2), both groups were divided according to sex. Female patients showed a tendency to lower perfusion in the right frontal lobe (fig.3). In male patients CBF in the right frontal lobe showed a tendency to decrease with HAM-D score (fig 4). Three patients have been rescanned; all had a lower HAM-D score at the second scan, one had HAM-D  $\leq 7$ . Two out of these three patients had a perfusion increase in the frontal lobes.

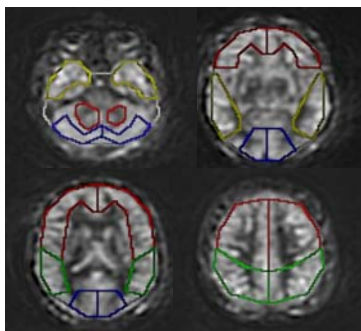


Fig 1. Selected ASL images from one patient showing regions of interest representing different lobes.

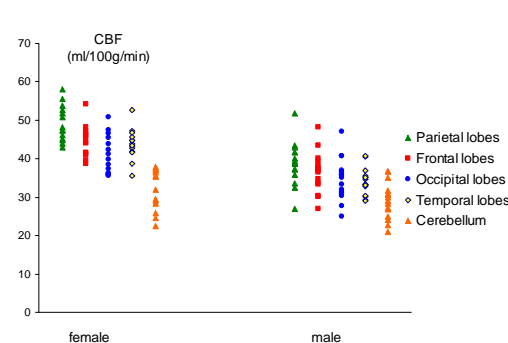


Fig 2. Perfusion values in the cerebral lobes for female and male controls.

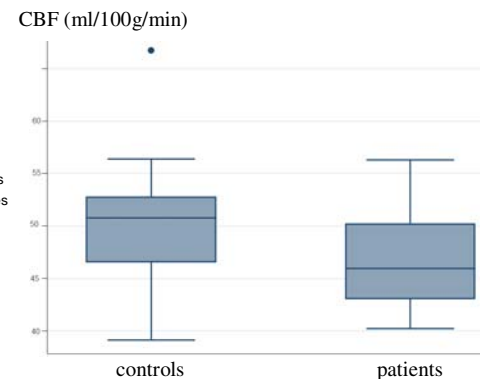


Fig 3. CBF in right frontal lobe for females (median, upper/lower quartiles, max/min).

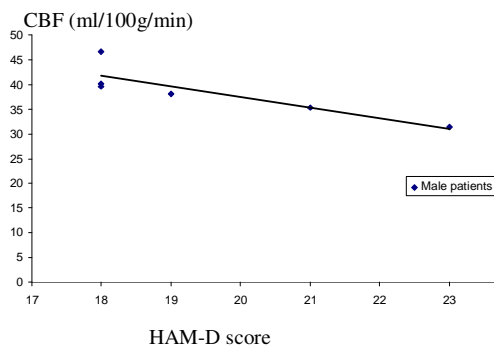


Fig 4. CBF in right frontal lobe for male patients and corresponding HAM-D score.

**Conclusion:** Our preliminary findings suggest that right frontal lobe perfusion may be involved in major depression, in consistency with previous studies (1,2). Although our patient group has a relatively mild depression with a mean HAM-D score of only 21, it was possible to find tendencies to perfusion abnormalities. Perfusion increase was found at the rescans. Thus 3D PC ASL might be a promising non-invasive perfusion technique for psychiatric studies.

## References

1. Takano H, Kato M, Inagaki A, Watanabe K, Kashima H. Time course of cerebral blood flow changes following electroconvulsive therapy in depressive patients measured at 3 time points using single photon emission computed tomography. *Keio J Med* 2006;55:153-160.
2. Drevets WC. Functional abnormalities in limbic and prefrontal cortical structures in major depression. *Prog Brain Res* 2000;126:413-431.