

Non-contrast Enhanced Three-dimensional MR Digital Subtraction Angiography at a Temporal Resolution of 100 msec.

M. Hori^{1,2}, N. Shiraga², Y. Watanabe³, S. Aoki⁴, S. Isono⁵, M. Yui⁶, and T. Araki¹

¹University of Yamanashi, Chuou, Yamanashi, Japan, ²Radiology, Toho University Omori Medical Center, Ota, Tokyo, Japan, ³University of Tokyo, Japan,

⁴Radiology, School of Medicine, Juntendo University, Japan, ⁵Toshiba Medical Systems, Japan, ⁶MRI Development dept, Toshiba Medical Systems, Japan

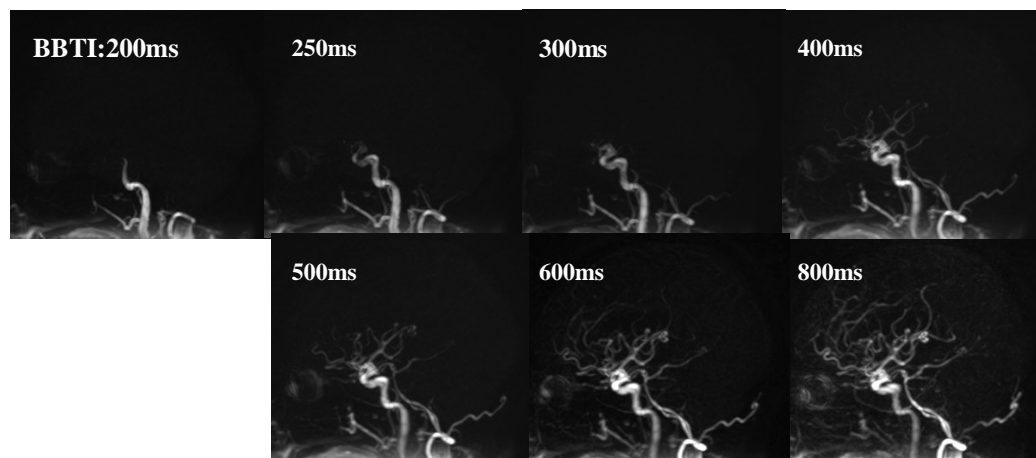
Introduction: To obtain both anatomical and hemodynamic information of intracranial arteries, contrast-enhanced MR angiography (MRA) has been a choice at clinical situations, instead of Time of flight (TOF) MRA which is vast majority methods for morphological MRA but provides no hemodynamic information. Moreover, arterial spin labeling (ASL) technique has been used to estimate cerebral blood flow quantitatively. Recently, dynamic MRAs based on ASL are introduced as a novel MRA technique providing both blood flow patterns and anatomical information without contrast material [1, 2]. One of them, time resolved MRA without contrast material can be achieved using three-dimensional (3D) true steady state free precession (SSFP) with selected inversion recovery (IR) pulse using multiple cardiac phase acquisitions. The feasibility of this new MRA technique, Time-Spatial Labeling Inversion Pulse (Time-SLIP) magnetic resonance digital subtraction angiography (MRDSA) to visualize neck arteries were reported as feasibility study at past ISMRM meeting [3]. Purpose of this study is to estimate the value of this technique in evaluation of intracranial arteries at 1.5T for clinical use.

Methods: All MR imaging were performed at a 1.5-T clinical imager (EXCELART VantageTM XVG, Toshiba, Japan). Three-dimensional TOF MRAs and Time-SLIP MRDSAs were acquired from ten healthy volunteers and three arterial steno-occlusive disease patients. Imaging parameters of time-SILP MRDSA were as follows: TR/TE=5.2/2.6 msec, flip angle=120°, field of view=280x280mm, matrix size =448x448, partition thickness/gap= 2.5-4/0mm. The labeling slab, approximately 90 mm. Time-SLIP MRDSAs were performed at various inversion time for black blood (BBTI) ranging from 150 to 1100 ms in increments of 50-100 ms. All imaging time of 3D MRDSA was up to approximately fifteen minutes because multiple data acquisition with varied delay time after IR pulse was needed. The labeling slab covered bilateral internal carotid arteries (ICAs) or unilateral ICA for MR imaging of blood supply from each ipsilateral side.

We evaluated 1) visualization of normal cranial arteries (internal carotid arteries, middle cerebral arteries, anterior cerebral arteries, posterior cerebral arteries, basilar arteries and vertebral arteries) on Time-SLIP 3D MRDSA in comparison with 3D TOF-MRA images on a workstation, 2) visualization of blood flow patterns from each ICA to the circle of Willis visually on 3D MRDSA performed in axial plane and 3) demonstration of intracranial arteries in patients with arterial steno-occlusive disease.

Results: In all volunteers, time-resolved 3D MRDSA without contrast material were successfully imaged and clearly visualized the branches of the cranial arteries ($P<0.01$), compared with 3D TOF-MRA. However, pseudo-stenoses were sometimes seen on 3D MRDSA images. 3D MRDSA containing hemodynamic information from unilateral ICA was obtained when the labeling slab covered ipsilateral ICA. In patients with arterial steno-occlusive disease, arrival delay of blood flow in the affected side and collateral blood flow were demonstrated on Time-SLIP MRDSA.

Discussion: Although this method is still time-consuming and needed to be improved, Time-SLIP 3D MRDSA provides hemodynamic information of the circle of Willis, and it may play an important role in assessing cranial arteries in clinical use without contrast material.



Figures. Serial maximum intensity projection images in sagittal plane of Time-SLIP MRDSA. Normal intracranial arteries are clearly visualized without contrast material.

Reference: [1] van Osch MJ, Hendrikse J, Golay X, et al. Non-invasive visualization of collateral blood flow patterns of the circle of Willis by dynamic MR angiography. *Med Image Anal.* 2006;10:59-70. [2] Miyazaki M, Lee VS. Nonenhanced MR angiography. *Radiology* 2008 248:20-43. [3] Yamashita Y et al. Selective visualization of Blood flow using SSFP Non-Contrast MRA with Time-Spatial Labeling Inversion Plus. *Proc. Intl. Soc. Mag. Reson. Med.* 14 (2006) 1928