

Multifunctional PET/MR imaging in small animal models

H. F. Wehr¹, M. S. Judenhofer¹, P. Martirosian², F. Maier¹, G. Reischl³, F. Schick², and B. J. Pichler¹

¹Laboratory for Preclinical Imaging of the Werner Siemens-Foundation, Department of Radiology, University of Tuebingen, Tuebingen, BW, Germany, ²Section on Experimental Radiology, Department of Radiology, University of Tuebingen, Tuebingen, BW, Germany, ³Radiopharmacy and PET-Center, Department of Radiology, University of Tuebingen, Tuebingen, BW, Germany

Introduction:

The combination of Positron-Emission-Tomography (PET) and MR in one device is a promising new imaging approach. Besides the ability to merge functional information from the PET with morphological information from the MR, the simultaneous acquisition of PET/MR allows multifunctional imaging, where fMRI or MR spectroscopy is performed along with PET data collection. Acquiring multi-parametric data allows on the one hand cross calibration studies, where the same parameter is assessed in PET and MR (e.g. perfusion), or on the other hand monitoring of metabolism on different levels (e.g. glucose consumption with PET and at the same time the BOLD signal with the MR).

Material and Methods:

A PET insert developed and built by our group was installed inside a 7 T small animal MRI scanner. For simultaneous PET/MR measurements a glioma mouse model was used. ¹H-Spectroscopy (PRESS, TR=2000 ms, TE=30 ms, voxel size=2.5x2.5x2.5 mm³) was performed on the tumor before and after administration of [¹¹C]Choline PET-tracer and the integral of the Choline peak in the MR signal was evaluated. The mice were injected with a MR contrast agent (Gd-DTPA) and T1-weighted 3D (FLASH, TR=16 ms, TE=4.06 ms, matrix=128x128x72, FOV=24x20x14 mm³) data sets of the enhancing area inside the brain were obtained. Simultaneously with the MR scans we obtained PET images of the mouse brain using different PET tracers. These were [¹¹C]Choline (for membrane activity), [¹⁸F]Fluoro-L-Thymidine (FLT) (for cell proliferation), and [¹¹C]Methionine (MET) (for amino acids). The uptake patterns of these PET tracers were compared with the spatial extent of the MR contrast agent enhancement. Furthermore simultaneous MR-ASL (FAIR, TR=4.1 ms, TE=2.05 ms, matrix=64x64, FOV=25x25 mm², slice thickness=1.2 mm) and [¹⁵O]Water PET perfusion studies were performed, the [¹⁵O]Water was injected and measured when the ASL sequence was running. We changed the breathing protocol of the mice to induce a change in perfusion. In addition to this we monitored the MR-BOLD signal with an EPI-sequence (TR=2000 ms, TE=49 ms, matrix=64x64, FOV=16x14 mm², slice thickness=1.0 mm) during the change of the breathing gas.

Results:

The Choline PET tracer injection did not alter the Choline-MR spectroscopy signal. A difference in the extent of the enrichment patterns between MR contrast agent, Choline, FLT and MET-PET was observed (Figure 1). A lower perfusion of the necrotic tumor parts (145±26 ml/min/100g) compared to thalamus (196±31 ml/min/100g) and cortex was observed in the MR-ASL signal as well as in the [¹⁵O]Water PET results (Figure 2). It was possible to detect a breathing protocol induced BOLD effect with MRI in the presence of the PET insert. Furthermore relative blood flow changes could be observed using [¹⁵O]Water PET and simultaneously MR-ASL.

Discussion and Conclusions:

The fact that MR spectroscopy was not influenced by the application of a PET tracer shows that the sensitivity of the PET, which is in the picomolar range, is higher than the one of MR spectroscopy (milimolar). The mismatch between MR contrast agent uptake patterns and PET-tracer enhancement might be important for tumor biopsy and therapy. The simultaneous measurement of ASL-MR and PET-Perfusion allows a quantitative comparison of the two methods, without the confounding influence of different physiological parameters. This can then be used for kinetic modeling of PET data (e.g. receptor uptake) or cross validation studies of perfusion imaging techniques. This study shows a high potential of PET/MR in research and diagnosis.

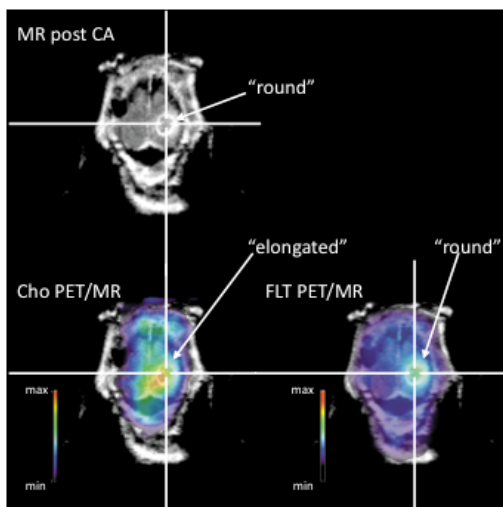


Figure 1: Mismatch between areas of the tumor enhanced with MR contrast agent and Choline and FLT PET-tracer.

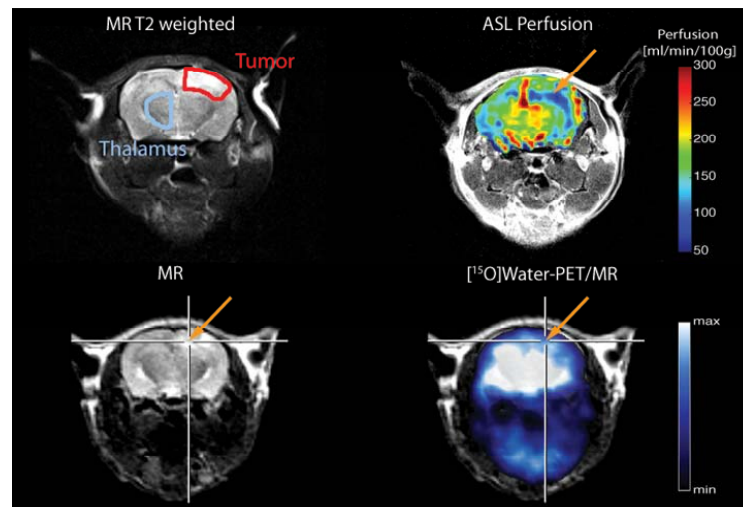


Figure 2: MR-ASL measurements as well as the simultaneously obtained [¹⁵O]Water PET indicate a lower perfusion in the necrotic parts of the tumor (arrow).