

Scaling methods for registration of pre- and post-androgen ablation MR prostate images

S. Riches¹, M. Partridge², G. S. Payne¹, V. A. Morgan¹, and N. M. deSouza¹

¹CRUK Clinical Magnetic Resonance Group, Institute of Cancer Research & Royal Marsden NHS Trust, Sutton, Surrey, United Kingdom, ²Department of Physics, Institute of Cancer Research & Royal Marsden NHS Trust, Sutton, Surrey, United Kingdom

Introduction: Radiotherapy planning in prostate cancer currently utilizes CT imaging for localization. MRI offers improved visualisation of the prostate gland with functional MR techniques further improving tumor localisation [1,2]. Use of MRI techniques for radiotherapy planning may allow greater efficacy of treatment by facilitating a targeted boost of radiotherapy to the tumor tissue. However, the use of androgen ablation prior to radiotherapy shrinks the prostate [3] and reduces discrimination between normal and malignant prostate tissue on morphological and functional MR techniques [4,5]. Therefore to model a radiation boost to the tumor based on functional MR requires data acquired before androgen ablation therapy to be registered with anatomical images obtained just prior to radiotherapy. This study evaluated the effect of assuming linear or bi-linear shrinkage of the prostate on the accuracy of identifying tumor position following androgen ablation therapy using lesions identified on T2-weighted images.

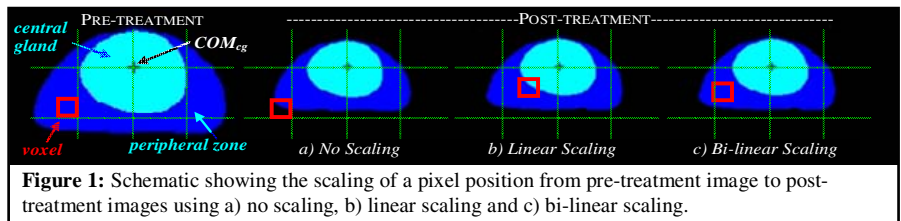
Method: 15 men (mean age 69, range: 55-75) with biopsy-confirmed prostate cancer who had been prescribed androgen ablation therapy were scanned using a 1.5T Intera clinical MR scanner (Philips Medical Systems, Best, Netherlands) with an endorectal receive coil (Philips), inflated with 55ml of air. Patients were imaged on diagnosis and after three months of hormone therapy. T2-weighted axial images (FSE, TR/TE=2000/90, 20 slices, 3mm thickness, 256x512 matrix, 140mm FOV) were acquired. An experienced radiologist drew regions of interest (ROI) around the whole prostate, the central gland and tumor (regions of low T2 signal intensity) on pre and post-treatment scans (Tum_{T2}). The prostate dimensions and percentage shrinkage of the whole prostate gland and central gland were calculated and compared. In-house software was used to compare three methods of registration of Tum_{T2} on pre treatment scan to post-treatment prostate (Figure 1):

- No scaling*: by correcting for shift in centre of mass of the central gland (COM_{cg}) and rotation only,
- Linear scaling*: by aligning the pre- and post-treatment COM_{cg} and isotropically scaling the entire gland about the COM_{cg},
- Bi-linear scaling*: Align the pre and post-treatment COM_{cg}. Within the central gland isotropic scaling performed about the COM_{cg}. In the peripheral zone, isotropic scaling performed about the COM_{cg} between the central gland border and whole prostate border.

For each method, location of the predicted tumor ROI (Tum_{pred}) was compared with Tum_{T2} outlined on post-treatment images. The number of overlapping Tum_{pred} and Tum_{T2} voxels were noted. The number of overlapping voxels as a fraction of the number of Tum_{T2} voxels and as a fraction of the number of Tum_{pred} were calculated as measures of sensitivity and specificity respectively. Accuracy was defined as the product of sensitivity and specificity. For the best method, the Tum_{pred} was expanded within the prostate by 5mm to assess accuracy of tumor localisation with realistic radiotherapy planning margins.

	Left-Right	Anterior-Posterior	Head-Foot
Mean Prostate Shrinkage (mm)	7±2	7±4	2±7
Shrinkage of prostate (%)	13±4	16±8	4±25
Shrinkage of central gland (%)	9±5	10±8	-2±39


Table 1: Mean and percentage shrinkage of the prostate and central gland after 12 weeks of androgen ablation.



Results: Table 1 shows the mean shrinkage of the prostate gland and percentage shrinkage of the whole prostate and central gland during treatment. There is significantly reduced shrinkage in the central gland compared with the whole gland along the left-right and anterior-posterior axis which shows greater shrinkage of peripheral zone tissue. Greater variability in the head-foot direction is due to the greatly-reduced resolution along this axis. Figure 2 shows the results of the three registration techniques for one patient. Table 2 shows the average sensitivity, specificity and accuracy for each registration technique. Simply overlaying the pre-hormone tumor outline over the post-hormone images give the best sensitivity, but poorest specificity as the majority of the tumor outline lies outside of the prostate. The sensitivity and specificity of the linear scaling methods is similar, but the specificity of the bi-linear scaling method is superior. With a 5mm intra-prostate expansion, the mean sensitivity of the bi-linear ROI was increased to 0.78 ± 0.18.

Registration Method	ROI			ROI + 5mm intra-prostatic expansion
	Sensitivity	Specificity	Accuracy	Sensitivity
No Scaling	0.53 ± 0.32	0.19 ± 0.36	0.13	0.69 ± 0.30
Linear Scaling	0.46 ± 0.23	0.36 ± 0.31	0.19	0.75 ± 0.19
Bi-linear Scaling	0.45 ± 0.24	0.45 ± 0.24	0.26	0.78 ± 0.18

Table 2: Sensitivity and specificity (mean ± sd) for the three registration methods over 15 patients.



Discussion: Shrinkage of the prostate during 12 weeks of androgen ablation therapy is greater in peripheral zone tissue than central gland tissue. Simply transferring prostate and central gland ROIs from pre-to post-treatment images has >50% sensitivity but low specificity due to the shrinkage of the prostate. Bi-linear scaling gives the best result because the increased fraction of shrinkage within the peripheral zone is accounted for. Expansion of the ROIs generated with the bi-linear scaling by 5mm resulted in a clinically acceptable error for planning of a radiotherapy boost.

Conclusion: Changes in shape in the prostate gland during androgen ablation treatment have been identified. A bi-linear model allows tumor identified on pre-treatment images to be adequately registered to post-treatment anatomical images. This should allow planning of a radiation boost to the tumor based on functional data acquired prior to androgen ablation.

References: [1] Ogura, K, *et al* Urology 2001; 57:721, Reinsberg, SA, *et al* 2007, AJR, 188:91-98 D' Amico, A. *et al*, 1998, Urology, 51, 287; [2] Mueller-Lisse UG *et al*. Radiology 2001; 221:380-390. [3] Riches, SF *et al*, Proc Intl Soc Mag Reson Med 2007; 2007:793. **Acknowledgements:** This work was supported by Cancer Research UK grant number C1060/A5117 and also NHS funding to the NIHR Biomedical Research Centre. SR is funded by a Personal Award Scheme Researcher Developer Award from the NIHR.