

Detection of Changes in T_1 Values in Normal Brain During Normobaric Hyperoxia

S. J. Mills¹, G. Thompson¹, G. A. Buonaccorsi¹, G. J. Parker¹, and A. Jackson¹

¹Imaging Science and Biomedical Engineering, School of Cancer and Imaging Sciences, University of Manchester, Manchester, United Kingdom

Introduction: Dissolved oxygen is paramagnetic and therefore reduces the T_1 value of tissue and blood[1]. The use of oxygen as a longitudinal relaxivity contrast agent has been investigated in a variety of tissues outside the brain[2]. With increasing interest in the oxygenation status of tumours and in the potential significance of changes during standard chemo-radiotherapy and anti-angiogenic therapy, change in oxygenation status is increasingly being investigated as a tumour and tissue response biomarker[2]. To the best of our knowledge no evidence has yet been reported indicating that the paramagnetic effects of dissolved molecular oxygen can be observed in the healthy brain. Our intention was to perform experiments to test the null hypothesis that no significant reduction in the T_1 of cerebral tissues is detected during normobaric hyperoxia in healthy volunteers.

Methods: Ethical approval was granted. Five young, healthy volunteers were imaged. Volume T_1 maps were acquired using variable flip angle spoiled gradient echo sequences (TE=1.1ms, TR=3.5ms; $\alpha=2^\circ, 5^\circ, 10^\circ, 16^\circ$; matrix 128x128x25, 1.8mmx1.8mmx4.2mm, 4 signal averages) on a Philips Achieva 3T MRI scanner with an 8 channel SENSE head coil (Philips Medical Systems BV, Best, Netherlands). A block design was used with 3 acquisitions on medical air (block 0), 11 on 100% O₂ (block 1), and 11 on medical air (block 2), with a temporal resolution of approximately 1.2 min. Prior to block 0 and between blocks 1 and 2 a phase contrast angiography (PCA) sequence was acquired for a separate investigation. A non-rebreathing mask was used for gas delivery at 15l.min⁻¹. Mean T_1 values were determined at each time point for each volunteer in 5 tissue types: splenium of corpus callosum (CC), deep white matter (DWM – left forceps minor), cortical grey matter (CGM – left paracentral lobule), thalamus (BG), and skeletal muscle (SkM - trapezius). VOIs were delineated on the initial acquisition and applied to the time series with an assumption of minimal volunteer movement (one volunteer was rejected due to significant movement). Data from each tissue VOI were averaged across the remaining volunteers and plotted against time.

Results: Example data in CGM are shown in figure 1. Baseline drift of unknown origin was noted in the T_1 values in all tissue types across all volunteers. As a first approximation it was assumed to be linear and unrelated to oxygen administration effects. This was therefore corrected by linear regression analysis on data from air-breathing blocks (0 and 2) (fig 1A). Residual values representing corrected ΔT_1 were calculated for each time point in comparison with the predicted baseline (fig 1B) and averaged across subjects (fig 1C). Mean values of corrected ΔT_1 in CGM across each block are shown in figure 1D. Following correction, significant ΔT_1 values were observed in each tissue during inhalation of 100% O₂. Table 1 shows the mean reduction in T_1 for each tissue during the normobaric hyperoxic phase (block 1) with 95% confidence intervals (CI), and the results of t-test analysis comparing the pre-hyperoxic and hyperoxic phases (block 0 vs block 1), the hyperoxic and post-hyperoxic phases (block 1 vs block 2), and the pre- and post-hyperoxic phases (block 0 vs block 2).

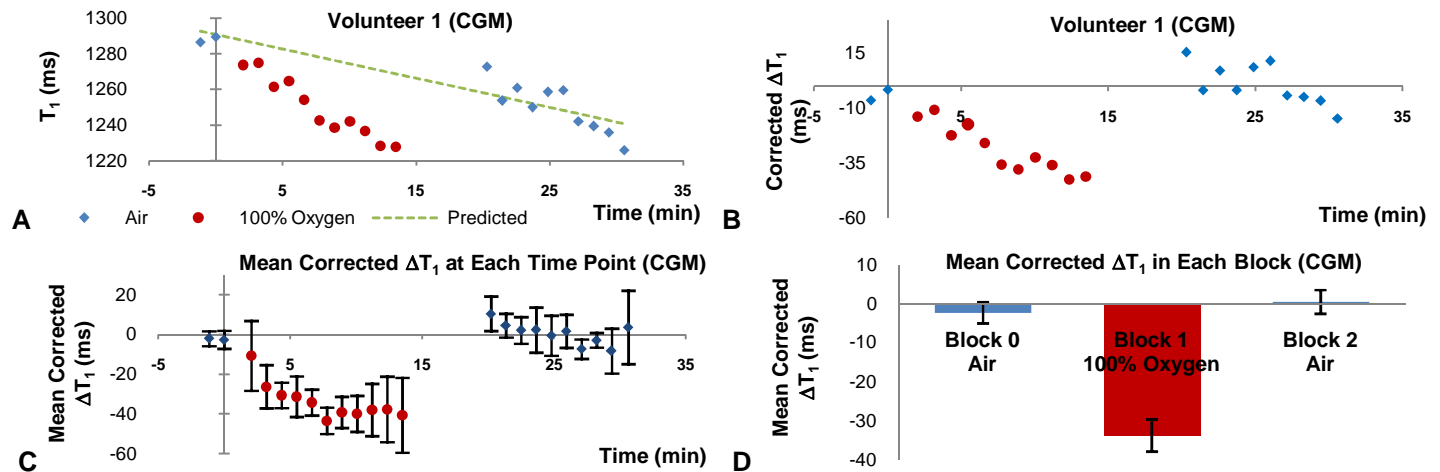


Figure 1: A) An example of the absolute T_1 value over time in a healthy volunteer in cortical grey matter showing normoxia (blue), hyperoxia (red) and a predicted baseline (green). B) Residuals of the observed minus the predicted T_1 to correct for baseline variation in the same volunteer. C) Mean ΔT_1 versus time in cortical grey matter for all included volunteers ($n=4$) showing 95% CI. D) Mean corrected ΔT_1 in each block showing 95% CI.

Tissue Type	CC	DWM	CGM	BG	SkM
Mean Baseline $T_1 \pm sd$ (ms)	1199±57	832±53	1176±120	1553±57	962±82
100% O ₂ ΔT_1 (ms) $\pm 95\% CI$	-8.0±5.0	-8.5±2.3	-33.8±4.1	-16.4±6.5	-10.1±3.3
unpaired t-test Block 0 vs 1	0.062	0.0025	<0.0001	0.040	0.001
one tail Block 1 vs 2	0.008	<0.0001	<0.0001	<0.0001	<0.0001
equal variance Block 0 vs 2	0.290	0.465	0.244	0.251	0.427

Table 1: Mean corrected ΔT_1 during hyperoxia with t-test comparison of T_1 before, during and after hyperoxia

between pre-hyperoxic and hyperoxic states in CC ($p=0.062$) although there was a significant change following the switch back to air ($p=0.008$). It is not clear whether the dominant effect reducing VOI T_1 values is an increase in dissolved tissue oxygen[3], an increase in dissolved blood plasma oxygen[4], or reduction in fractional blood volume[5]. Further investigation with a longer block 0 and randomisation to a control block 1 will allow testing of the assumption of baseline collinearity and further characterisation of the T_1 drift. Obtaining rCBV maps during plateau phase may clarify the relative contribution of underlying physiological changes to the T_1 change.

Acknowledgements: This work was funded by Cancer Research UK Grants numbers C237/A6295, C30033/A9809, and C21274/A7473.

References:

- 1) Uematsu, H., et al., J Comput Assist Tomogr, 2007. **31**(5): p. 662-5.
- 2) O'Connor, J.P., et al., Magn Reson Med, 2007. **58**(3): p. 490-6.
- 3) Duong, T.Q., C. Iadecola, and S.G. Kim, Magn Reson Med, 2001. **45**(1): p. 61-70.
- 4) Berkowitz, B.A., Magn Reson Imaging, 1997. **15**(1): p. 123-6.
- 5) Watson, N.A., et al., Eur J Anaesthesiol, 2000. **17**(3): p. 152-9.

Discussion: The method described here shows significant ($p<0.05$) decreases in longitudinal tissue relaxivity during normobaric hyperoxia in DWM, CGM, BG and SkM in healthy volunteers, following correction for baseline drift. No significant difference was seen