

# 1H-MR Spectroscopy Utilizing a 1T Open MR System: Initial Clinical Results

T. G. Perkins<sup>1</sup>, J. B. Murdoch<sup>1</sup>, and B. Goss<sup>2</sup>

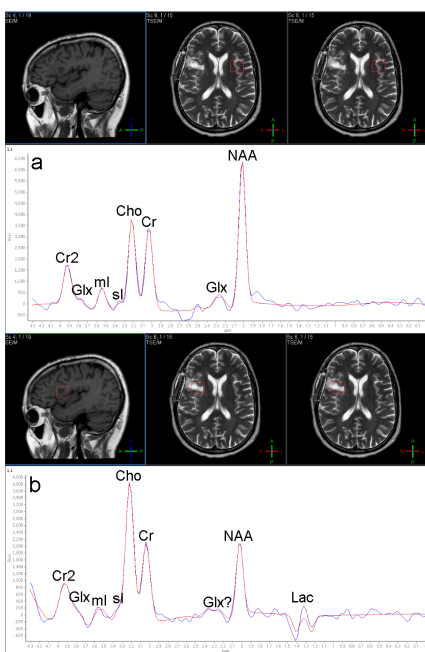
<sup>1</sup>Philips Healthcare, Cleveland, OH, United States, <sup>2</sup>New Mexico Cancer Center, Albuquerque, NM, United States

**Introduction:** Proton MR Spectroscopy (<sup>1</sup>H-MRS) has been established for many years as a valuable tool in the study and diagnosis of neurological disorders, in particular for oncological follow-up of post-treatment brain tumors. Recently, 1T spectra were acquired on patients with normal brain chemistry to explore the clinical utility of <sup>1</sup>H-MRS on a commercially available high field (1.0T) open MR system, as well as to compare the signal-to-noise ratio (SNR) and spectral quality of the 1.0T spectra with data collected at 1.5T and 3.0T<sup>1</sup>. Based on the success of this previous study, a clinical test is underway to evaluate the quality of spectra that can be obtained on patients with brain pathology within an oncology practice. Initial results of this study are presented here.

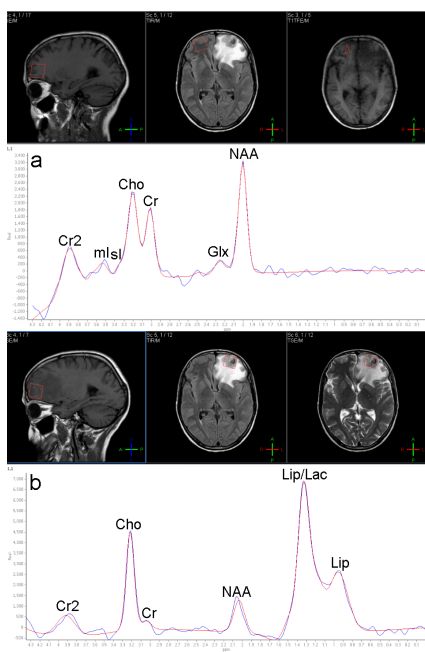
**Methods:** Water-suppressed single voxel <sup>1</sup>H-MRS (SVS) of the brain was performed with Point Resolved Spectroscopy (PRESS) localization on a clinical Panorama HFO 1.0T open whole-body MR system (Philips Healthcare, Best, The Netherlands) using a four-channel Solenoid Technology (ST) SENSE head coil for both MRI and MRS. For this clinical test, PRESS localized spectra were added to the standard brain protocols for patients undergoing routine MR brain imaging. Data were acquired using a TR/TE of 1500/144 ms, voxel sizes ranging from 3.4 to 8.0 cc (dependent upon tumor size), 192 signal averages, a sampling bandwidth of 1 kHz, and a scan time of 4 min 48 s. Taking advantage of the open magnet configuration, automatic left-right and superior-inferior movement of the patients in the magnet was performed so that the PRESS voxels were acquired at magnet isocenter. All spectra were processed using SpectroView (Philips Healthcare) and are presented with the acquired spectrum (red), fitted spectrum (blue) and, if included, the fitted baseline correction (green). Peak ratios are reported using the area (or at times the height) of the spectral peaks.

**Results:** Figure 1 shows SVS <sup>1</sup>H-spectra acquired on a 50 yr male post glioblastoma resection. While the contralateral spectrum shows normal choline (Cho) to creatine (Cr) and N-acetyl aspartate (NAA) to Cr ratios (Cho/Cr = 1.04, NAA/Cr = 1.51), the resected area shows elevated Cho and reduced NAA (Cho/Cr = 1.75, NAA/Cr = 0.75), as well as the presence of an inverted lactate doublet, consistent with remaining active tumor. Figure 2 shows the SVS <sup>1</sup>H-spectra for a 44 yr female diagnosed with metastatic non-small-cell lung cancer. The Cho/Cr and NAA/Cr ratios are consistent with mildly abnormal (right frontal) and malignant metastatic (left frontal) tissue: (Cho/Cr)<sub>R</sub> = 1.22, (NAA/Cr)<sub>R</sub> = 1.73, (Cho/Cr)<sub>L</sub> = 11.60, (NAA/Cr)<sub>L</sub> = 3.82 (These are peak *height* ratios – the Cr peak in the tumor is so small that its “area” includes some baseline). It is remarkable that the two spectra are not significantly affected by local magnetic susceptibility, given the close proximity of the voxels to the brain/skull interface, but such robustness is a benefit of 1.0T. Figure 3 shows the spectrum obtained within a midbrain astrocytoma. The spectrum, which was acquired with a completely oblique 18 x 18 x 16 mm voxel to fully fit within the astrocytoma, shows elevated choline (Cho/Cr = 1.43) with significantly reduced NAA (NAA/Cr = 0.11), an inverted lactate doublet, and the presence of myo-inositol (mI), all of which are consistent with a grade III astrocytoma<sup>2</sup>. Spectral simulation of the mI proton resonances at 3.54 ppm shows that, at 1.0T, these resonances appear as a singlet at TE = 144 ms. At higher field strengths, this is not the case.

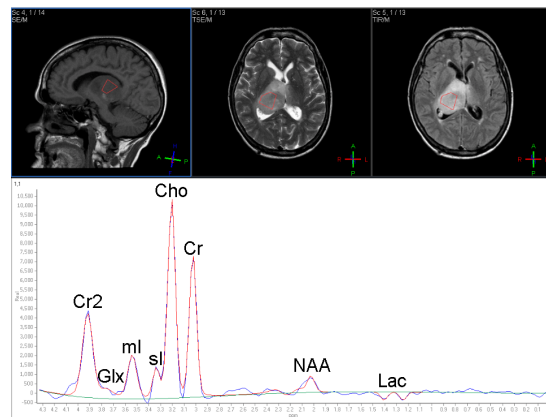
**Discussion and Conclusion:** Although the trend continues towards higher field strengths for increased SNR and spectral dispersion, this extension of previously presented work to real-world clinical cases demonstrates that high quality <sup>1</sup>H-MRS can be performed with a high field open magnet configuration. With the growing number of habitus-limited radiology studies due to the increasing numbers of obese patients<sup>3</sup>, as well as the potential for performing MR radiation therapy planning using both imaging<sup>4,6</sup> and spectroscopy<sup>7</sup>, a 1.0T open MR system has the potential to become a valuable tool in the diagnosis and treatment of a variety of disease processes.



**Fig. 1:** 50 yr male following glioblastoma resection, radiation, and chemotherapy. These spectra were acquired three weeks following resection. (a) The contralateral normal tissue presents a typical PRESS TE 144 spectral pattern. (b) The remaining tumor area shows elevated choline, reduced NAA, and an inverted lactate doublet.



**Fig. 2:** 44 yr female diagnosed with metastatic non-small-cell lung cancer. The spectra were acquired three weeks following diagnosis. (a) The normal tissue presents a typical PRESS TE 144 spectral pattern. (b) The lesion spectrum indicates aggressive growth, with highly elevated choline. Note the position of the selected voxels relative to the brain/skull interface.



**Fig. 3:** 66 yr female with a midbrain astrocytoma. The spectrum shows elevated choline, significantly reduced NAA, and an inverted lactate doublet, all consistent with a grade III astrocytoma. Note the excellent spectral resolution, including both myo-inositol (mI) and scyllo-inositol (sI) resonances.

## References

- Perkins TG, Kruiskamp M, Murdoch J, Hitt D, Orrison WW, *Proc. Ann. Meet. Intl. Soc. Magn Reson. Med.* 15, 2253 (2007)
- Castillo M, Smith JK, Kwok L, *AJNR* 21, 1645 (2000)
- Uppot R, Sahani V, Hahn P, Karla M, Saini S, Mueller P, *Radiology* 240, 435 (2006)
- Shuman WP, Griffin BR, Haynor DR, Johnson JS, Jones DC, Cromwell LD, Moss AA, *Radiology* 156, 143 (1985)
- Mah, D, Steckner M, Palacio E, Mitra R, Richardson T, Hanks G, *Med. Phys.* 29, 2541 (2002)
- Krempien RC, Schubert K, Zeirhut D, Stecker MC, Treiber M, Harms W, Mende U, Latz D, Wannenmacher M, Wenz F, *In. J. Rad. Onco.* 53, 1350 (2002)
- Payne GS, Leach MO, *BJR* 79, S16 (2006)