

## Contrast-Enhanced Magnetic Resonance mammography for screening of the contralateral breast in patients with diagnosed breast cancer

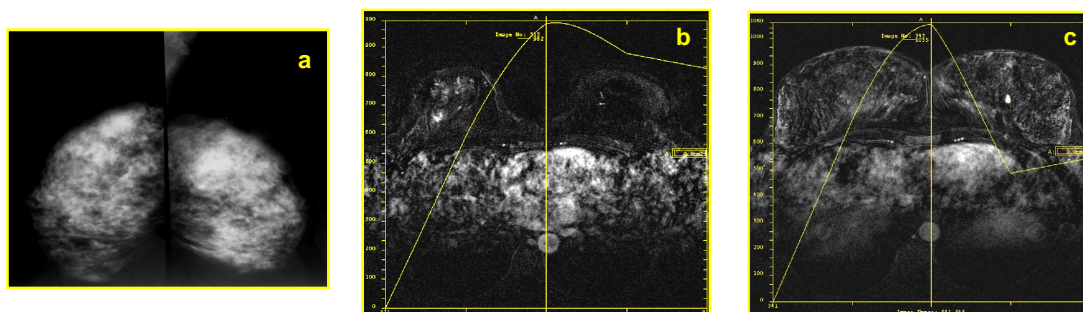
F. Pediconi<sup>1</sup>, S. Cagioli<sup>2</sup>, V. Dominelli<sup>2</sup>, M. Luciani<sup>2</sup>, V. Martino<sup>2</sup>, C. Catalano<sup>3</sup>, and R. Passariello<sup>4</sup>

<sup>1</sup>Dept. of Radiological Sciences, La Sapienza University of Rome, Rome, Italy, <sup>2</sup>of Radiological Sciences, La Sapienza University of Rome, Rome, Italy, <sup>3</sup>of Radiological Sciences, La Sapienza University of Rome, Rome, Italy, <sup>4</sup>of Radiological Sciences, La Sapienza University of Rome, Rome, Italy, Italy

**PURPOSE:** To determine the role of contrast-enhanced Magnetic Resonance Mammography (CE-MRM) for evaluation of the contralateral breast in patients with recently diagnosed breast cancer.

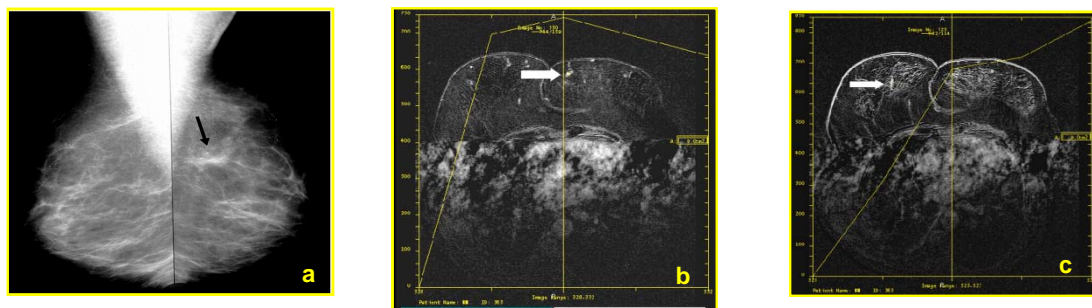
**MATERIALS AND METHODS:** 118 consecutive patients with proven unilateral breast cancer and negative contralateral breast at physical examination, ultrasound and x-ray mammography underwent CE-MRM at 1.5 T using a bilateral surface breast coil. Axial 3D T1-weighted GRE images were acquired before and at 0, 2, 4, 6, and 8 min after administration of 0.1 mmol/Kg BW gadobenate dimeglumine. Breast density and level of suspicion for contralateral breast lesions was evaluated according to the BI-RADS lexicon. Results were compared with histological findings after biopsy or surgery.

**RESULTS:** CE-MRM revealed contralateral lesions in 28/118 (24%) patients. Eight (28.6%) of these patients were classified as BI-RADS 4 (suspicious for malignant lesions) and underwent biopsy. The remaining 20 (71.4%) patients were classified as BI-RADS 5 (highly suggestive for malignant lesions) and underwent surgery. At histology 22 lesions were confirmed as malignant (TP lesions) whereas 6 lesions were fibroadenomas (FP lesions). No false negative lesions were detected and none of the patients with fibroadenomas was classified as BI-RADS 5. The sensitivity, specificity and diagnostic accuracy, PPV and NPV for the detection of malignant contralateral lesions was 100%, 93.8%, 94.9%, 78.6% and 100% respectively



*Fig.1:* Mammography (mediolateral oblique view): shows the presence of a mass with irregular margins, in the upper outer quadrant of the right breast (a). Contrast enhanced MR mammography subtracted images confirm the presence of a suspicious lesion with irregular margins in the upper outer quadrant of the right breast (b) and shows the presence of a lesion with regular margins and suspicious enhancement pattern in the contralateral breast (c)

**CONCLUSIONS:** CE-MRM is a highly accurate technique for the detection of synchronous contralateral cancer in patients with newly diagnosed breast cancer and should be introduced as a screening examination in patients with proven breast cancer before surgery.



*Fig 2* Conventional mammography (mediolateral oblique view) reveals a parenchymal distortion (black arrow) in the upper inner left breast (a). MR mammography confirms the presence of a lesion in the upper inner left breast with suspicious morphology and enhancement (b) and shows the presence of another lesion in the contralateral breast (homogeneous enhancement and type I curve).