

# Using Hyperpolarized 3He MRI to Distinguish Asthmatics from Healthy Subjects

Y. Sun<sup>1</sup>, S. Krinzman<sup>2</sup>, T. Tan<sup>1</sup>, T. Bishop<sup>2</sup>, A. Sosa<sup>2</sup>, S. Rajan<sup>2</sup>, A. Reno<sup>1</sup>, Y-S. Tzeng<sup>3</sup>, S. Zhalhdoust-Sani<sup>3</sup>, K. R. Lutchen<sup>3</sup>, J. M. Madison<sup>2</sup>, and M. S. Albert<sup>1</sup>

<sup>1</sup>Radiology, University of Massachusetts Medical School, Worcester, Massachusetts, United States, <sup>2</sup>Div of Pulmonary Medicine, University of Massachusetts Medical School, Worcester, Massachusetts, United States, <sup>3</sup>Biomedical Engineering, Boston University, Boston, Massachusetts, United States

## Introduction

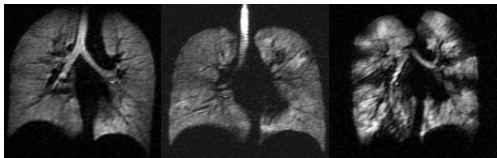
Hyper-responsiveness and heterogeneous constriction of the airways are cardinal characteristics of asthma, which leads to inhomogeneous ventilation distribution in the lungs. Although hyperpolarized (HP) <sup>3</sup>He MRI has been used in the past to characterize the physiology of asthmatic lungs (1, 2), we wanted to determine whether ventilatory defects detected with <sup>3</sup>He MRI correlate with the presence and severity of asthma.

## Methods

The HIPAA-compliant research protocol in this study was approved by the local Institutional Review Board. Informed consent was obtained from all recruited subjects. Data were obtained from 4 severe asthmatics, 18 mild-to-moderate asthmatic, and 7 healthy subjects. HP <sup>3</sup>He static ventilation MRI scans were performed with a Fast Gradient Echo pulse sequence acquiring coronal multislice images with the following parameters: 46 cm FOV, 0.75 PhaseFOV, 128×256 matrix, 13 mm slice thickness, TE/TR 1.2 ms/5 ms, and interleaved data acquisition. For each scan, 1 liter of an approximately 33% HP <sup>3</sup>He- 67% N<sub>2</sub> mixture was administered for the subject to inhale. Five pulmonologists who are blinded to patient's information evaluated the images with a scoring system that included counting of the number of defects and scoring the degree of ventilation heterogeneity. The number of defects (Def) were counted as 1-5, and 6 or more. The ventilation heterogeneity (Het) was scored as 0=none, 1=mild, 2=moderate, 3=severe. The two scores were summed to obtain a total score (Tot). The scores from the 5 pulmonologists were averaged together and Receiver operating characteristic (ROC) analysis was used to determine if the scores could distinguish asthmatics from normals.

## Results and Discussion

HP <sup>3</sup>He MR ventilation baseline images from a representative healthy, mild-to-moderate asthmatic, and severe asthmatic subject are shown in Figure 1.



**Figure 1.** Ventilation HP <sup>3</sup>He MR images from a representative healthy subject (A), mild-to-moderate asthmatic (B), and severe asthmatic(C).

	Het	Def	Tot
Healthy	0.5 ± 0.63	0.64 ± 1.16	1.14 ± 1.58
Mild-moderate	1.25 ± 0.96	2.75 ± 2.48	4.0 ± 3.29
Severe	2.5 ± 0.52	5.81 ± 0.75	8.31 ± 1.01

**Table 1.** The ventilation heterogeneity score (Het), number of defects score (Def), and sum of the two scores (Tot), as scored by pulmonologists for the three subject groups.

The HP <sup>3</sup>He MR ventilation images suggest fairly uniform homogeneous ventilation with Het = 0.5 ± 0.63, Def = 0.64 ± 1.16, Tot = 1.14 ± 1.58 for healthy subjects. In subjects with asthma, the scores clearly increased with disease severity with Het = 1.25 ± 0.96, Def = 2.75 ± 2.48, Tot = 4.0 ± 3.29 for mild to moderate asthmatics, and Het = 2.5 ± 0.52, Def = 5.81 ± 0.75, Tot = 8.31 ± 1.01 for severe asthmatics. The heterogeneity and defect scores were significantly different (p < 0.05) between healthy, mild to moderate and severe asthmatics. Intra-observer reliability was 0.73 for heterogeneity scores and 0.95 for defect scores. The Inter-observer reliability was 0.79 for heterogeneity scores and 0.86 for defect scores. ROC analysis showed total score had high specificity (95% for Tot=4) but low sensitivity (45% for Tot=4) in distinguishing mild-moderate asthmatics from normal subjects. In distinguishing severe asthmatics from normals, however, a Tot=5 yielded 96% specificity and 98% sensitivity. The area under the ROC curve (AUC) gave similar values for both the defect (0.75) and heterogeneity scores (0.73), suggesting that the ventilation heterogeneity score had equal discriminating value compared to the defect score.

## Conclusions

The amount of ventilation heterogeneity and the number of defects correlated with the presence and severity of asthma, using baseline images obtained with HP <sup>3</sup>He MRI. We have identified two characteristic patterns of ventilatory disturbance in asthma (heterogeneity and number of defects) which correlate with severity. The results further suggest that while ventilation is abnormal even in mild-to-moderate asthmatics, the degree of abnormality allows reliable discrimination of an asthmatic lung only for more severe asthmatic conditions.

**References:** 1.EE de Lange, et al., J Allergy Clin Immunol. 2007;119:1072. 2.EE de Lange, et al., Chest. 2006;130:1055.