

Evaluation of combined magnetic resonance and bioassay methods for quantitation of human liver steatosis

Y. Boulanger¹, M. Ruel¹, A. Khiat¹, L. Lepanto¹, M. Chagnon², C. Kauffman¹, A. Tang¹, L. Gaboury³, and G. d'Assignies¹

¹Radiologie, CHUM, Montréal, Québec, Canada, ²Mathématiques et statistique, Université de Montréal, Montréal, Québec, Canada, ³Anatomo-pathologie, CHUM, Montréal, Québec, Canada

Introduction

Fatty liver diseases or steatosis are increasingly common as a result of the obesity and diabetes epidemics. Asymptomatic, it can often lead to more severe diseases like fibrosis or cancer (1). The gold standard method to detect steatosis is the visual histopathological analysis of a liver sample collected by biopsy but the procedure is both invasive and painful and presents some risks for the patient health. In addition, the very small liver sample may not be representative of the whole liver. In this project, the ability of three MR techniques (dual-echo in phase/out of phase imaging (DEI), MRS and diffusion-weighted imaging (DWI)) and several bioassays to detect and quantitate liver steatosis was determined by evaluating correlations with semi-automatic segmentation of histopathology liver slices (HIS-S) as a reference. Methods were analyzed individually and in combination.

Methods

Patients: Twenty liver steatosis patients diagnosed with liver steatosis confirmed by histopathologic analysis were recruited.

Histopathology (HIS-S): Entire histopathology slides from a liver biopsy sample were scanned using a Nanozoomer slide scanner and the analysis of fat fraction (FF) was performed with a semi-automatic vacuole segmentation procedure developed with the MATLAB software.

MR: All MR experiments were performed during breath holding on a GE Signa 1.5 T instrument using the body and phase-array coils.

MRS: Single-voxel proton MRS data were acquired in three different areas of the liver (lower, central and upper locations) using the PROBE protocol with the PRESS sequence. Acquisition parameters were: voxel size = $2 \times 2 \times 2 \text{ cm}^3$, TE = 30 ms, TR = 1200 ms, number of scans = 16, water suppression = off, total acquisition time = 22 s. MR spectra were processed and quantified using *LCModel*. T1, T2, proton density and tissue density corrections were applied (2).

DEI: The fast spoiled gradient-recalled (SPGR) dual-echo sequence was used for DEI data acquisition using TR = 140 ms, TE = 2.2 and 4.4 ms, flip angle = 90° , total acquisition time = 17 s. Axial slices covering most of the liver were used with a thickness of 7 mm and a gap of 3 mm. The fat fraction (FF-DEI) was calculated in three circular regions of interest whose locations corresponded to those used for MRS data after T2*-correction of signal intensities.

Bioassays: Bioassays of blood and urine metabolites and enzymes relevant to the liver function were performed: fasting glucose, creatinine, total bilirubin, albumine, iron, transferrin, cholesterol, triglycerides, HDL, LDL, HBA1C, fructosamine, AP, ALT, AST and prothrombin time.

Statistical analyses: Correlations between MR or bioassay results and FF-HIS-S were analyzed using Pearson correlation tests. To evaluate the possibility of improving the reliability by combining results, partial correlation tests were performed using FF-MRS or FF-DEI values as control variable and each bioassay or other MR result as secondary variable. Statistical significance was set at $p < 0.05$.

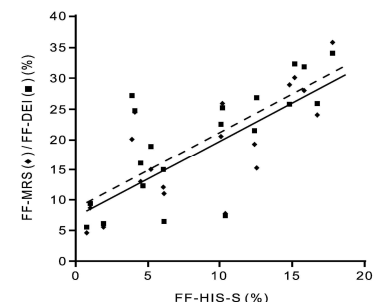
Results

Table 1 presents statistically significant correlations between noninvasive MR or bioassay results and the fat fractions determined by semi-automatic vacuole segmentation. Strong correlations were found for both FF-MRS and FF-DEI (Figure 1) as well as for the ALT, cholesterol and LDL. No significant correlation was found for DWI or other bioassays. No combination of two parameters could improve the correlation coefficients measured for FF-MRS or FF-DEI with FF-HIS-S.

Table 1: Statistically significant correlations between MR or bioassay results and FF-HIS-S for steatosis patients

Parameter 1	Parameter 2	r	p
FF-MRS	FF-HIS-S	0.773	< 0.001
FF- DEI		0.740	< 0.001
ALT		0.474	0.047
Cholesterol		0.649	0.004
LDL		0.605	0.010

Figure 1: Graph showing the correlation between FF values measured by MRS (♦, full line) and DEI (■, dotted line) and FF values measured by HIS-S in three liver voxels for steatosis patients.



Discussion

This study demonstrated that both MRS and DEI are sensitive to the level of liver steatosis as demonstrated by strong correlations with fat fractions determined by segmentation of the histology slice prepared from a biopsy sample. No combination of MR and bioassay parameters could improve the correlation strength. Both DEI and MRS methods have a strong potential for the noninvasive quantitation of liver steatosis.

References

- [1] Farrell GC & Larter CZ, Nonalcoholic fatty liver disease: from steatosis to cirrhosis. *Hepatology* **43**: S99-S112, 2006.
- [2] Longo R *et al.*, Proton MR spectroscopy in quantitative in vivo determination of fat content in human liver steatosis. *J Magn Reson Imaging* **5**: 281-285, 1995.