

# **Three dimensional $^1\text{H}$ magnetic resonance spectroscopy in breast cancer as an indicator of therapy response. A pilot study.**

**S. Gruber<sup>1</sup>, W. Bogner<sup>2</sup>, M. Chmelik<sup>3</sup>, K. Pinker<sup>3</sup>, L. Ponhold<sup>3</sup>, M. Krssak<sup>3</sup>, and S. Trattnig<sup>3</sup>**

<sup>1</sup>Dept. Radiology, MR-Centre of Excellence, Medical University of Vienna, Vienna, Austria, <sup>2</sup>Dept. Radiology, MR-Centre of Excellence, Medical University of Vienna, Austria, <sup>3</sup>Dept. Radiology, MR-Centre of Excellence, Medical University of Vienna

**Introduction:** Breast cancer is one of the most common cancers of the female population in the western world. Early diagnoses, and monitoring of early response to therapy are the key factors in the treatment of breast cancer. The combination of magnetic resonance techniques, in particular high-resolution magnetic resonance imaging (MRI), contrast-enhanced MRI (DCE-MRI) and three dimensional magnetic resonance imaging (3D-MRSI) provides high sensitivity and specificity for the detection of breast lesions at 3 Tesla (1,2). Furthermore, MR-based methods may become an important tool to quantitatively evaluate the early response of breast cancer patients to neoadjuvant chemotherapy. Early evaluation of chemotherapy may improve therapy and, therefore, success of treatment. In this study, a high resolution 3D-MRSI protocol at 3 Tesla was used in female breast cancer patients before and after chemotherapy. The sequence was designed to cover a large fraction of the breast in a clinically acceptable measurement time of approximately 10-12 minutes. Results before and after chemotherapy were compared in three patients.

**Methods and Materials:** In total three patients with confirmed cancer (via biopsy) were investigated on a 3T system (Siemens Tim Trio, Syngo VB15, Erlangen, Germany) using a 4 channel breast coil before and during the chemotherapy (follow-up). Two of the patients underwent one follow up measurement (after the first two therapy cycles) and one of them two follow-up measurements (after the first two and after four therapy cycles). Written informed consent, according to the guidelines and approval of the local review board was obtained from all patients prior to the study. After performing a standard imaging protocol including high-spatial-resolution T1-VIBE and T2-STIR, 3D-MRSI was applied. For 3D-MRSI a sequence with PRESS pre-selection was used for all measurements (TR/TE = 750/145ms). The sequence included spectral water and fat suppression and spatial outer volume suppression. Nominal voxel size was set to 1 cm x 1 cm x 1 cm in all measurements. The Field of View (FOV) was individually adjusted to cover the whole breast. Number of phase encoding steps were chosen to match the voxel size with the smallest possible FOV, resulting between 10 and 16 phase encoding steps in each of the three spatial directions. Weighted k-space sampling was used. Acquisition weighting was performed using a hamming-filter (100%) and 3-10 averages per measurement. Before processing, the data were zero filled to  $16 \times 16 \times 16$  voxels. Primary data spectral processing was performed within SyngoMR platform and. Additionally data from Cho-containing voxels were processed using LCModel to obtain signal-to-noise ratios of choline (SNRCho) signal.

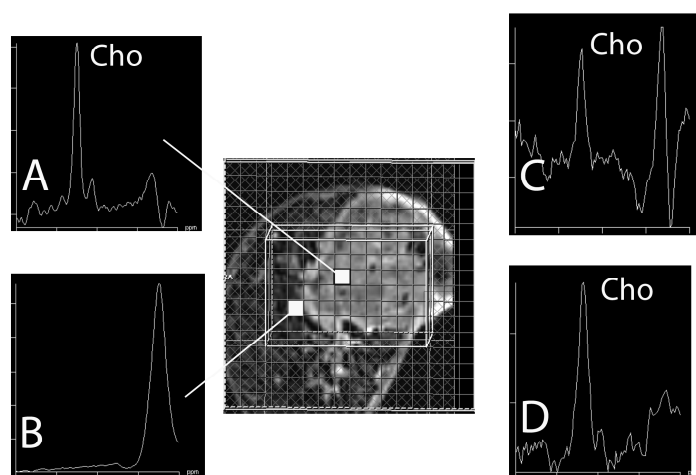
**Results:** In patients S1 and S2 SNRCho > 5 in 42 of 51 (82 %) and 8 of 11 (73%) voxels within the tumor (based on MRI) prior to chemotherapy. In the follow up measurements no Cho was detected in these two patients. In the patient S3 Cho was detectable in 225 of 324 voxels (69%) within the MRI detectable tumor. After the first two therapy cycles SNRCho decreased uniformly in most observed voxels, nevertheless Cho was detectable in 95 of 130 (73%) voxels. After four therapy cycles SNRCho increased again and Cho was detectable in 215 of 280 (77%) voxels within the tumor.

## **Discussion and Conclusion:**

In this pilot study we could perform 3D-MRSI in three patients with breast cancer before and after chemotherapy. Compared to previous studies which applied single voxel MRS or 2D-MRSI larger fraction of the breast could have been covered. In all patients with confirmed diagnosis of cancer, Cho was detectable in more than one slice before chemotherapy, pointing out the importance of 3D-MRSI. Kvistad et al. observed that a subject undergoing neoadjuvant chemotherapy had a detectable Cho peak before treatment, but, after treatment, the Cho resonance was no longer detectable. We could reproduce these results, in two patients. However, in the third patient the percentage of tCho containing voxels remained approximately constant. In the second of the two measurements the SNRCho was reduced approximately by 50% However, SNRCho of the third measurement was comparable with the first measurement.

In conclusion, these results suggest, that quantification of choline based on SNR and linewidth is not satisfactory. Approaches for absolute quantification are necessary for future applications, which would allow more reliable monitoring of the response to chemotherapy in breast cancer.

**Fig 1.** Shows two chosen spectra from the first measurement of patient S3. The left top one (A) with detectable Cho was acquired within the tumor. The spectra without detectable Cho (B) was acquired from normal appearing tissue. The right spectra were acquired after the first two therapy cycles (top, C) and after four therapy cycles.



**References:** [1] Gruber et al., #2750, ISMRM 3.-9. May 2008, Toronto, Canada; [2] Bogner et al., RSNA Nov. 30 – Dec. 5, 2008, Chicago, USA; [3] Kvistad et al., J Magn Reson Imaging, 1999. 10(2): p. 159-64