

Image based second order shimming for fat suppressed bilateral breast imaging at 3T

M. Schär^{1,2}, R. H. El Khouli³, A. W. Simonetti⁴, R. Holthuisen⁴, and D. A. Bluemke^{1,3}

¹Russel H. Morgan Department of Radiology and Radiological Science, The Johns Hopkins University School of Medicine, Baltimore, MD, United States, ²Philips Healthcare, Cleveland, OH, United States, ³Department of Radiology and Imaging Sciences, National Institute of Health/Clinical Center, Bethesda, MD, United States, ⁴Philips Healthcare, Best, Netherlands

Introduction:

Breast MRI is ideally suited for preoperative staging of the ipsilateral and contralateral breast in patients with Breast Imaging Reporting and Data System (BIRADS) category 5 and 6 lesions or for screening women who are at increased risk for breast cancer [1]. The increased available signal-to-noise ratio at 3T compared to 1.5T should allow for higher spatial resolution imaging. Initial experience at 3T has shown improved differential diagnosis of enhancing lesions when compared with 1.5T [2,3]. Homogenous fat suppression is crucial in breast MRI but remains challenging due to inhomogeneities of the static magnetic field B_0 . In this study localized image based higher order shimming is compared to conventional volume linear shimming first with manual selection of the shim region of interest (ROI) and then with an automated routine.

Methods:

Two adapted versions of a custom made shimtool [4] were implemented on a 3T Achieva whole body scanner (Philips Healthcare, Best, The Netherlands). The shimtool calculates higher order shim correction terms based on an acquired B_0 -map optimized for a selected ROI. Version A necessitates manual interactions to load the B_0 -map, to draw an ROI if the default ROI is too or not enough selective, and to unwrap the phase map in case wraps occurred. This process takes approximately 2 minutes including calculation of shim values. Version B starts after the acquisition of the B_0 -map, loads the map, determines the ROI based on segmentation of the breasts and unwraps the map all fully automatically. This process can run in the background while another image series, e.g. a SENSE reference scan, is acquired.

Performance of the 2nd order image based shim (IBS) was compared to the scanner's linear volume shim in 42 patients. Patients were scanned in the prone position using either a 4 or 7 channel SENSE breast coil. Axial B_0 -maps covering both breasts were acquired with a ΔTE of 2.3ms to keep signal from water and fat in phase. Shim values were determined using shimtool A in the first 21 patients and shimtool B in the second 21 patients. Both shim methods (volume and IBS) were applied in axial, T1-weighted RF-spoiled segmented gradient echo images acquired with the following parameters: 3D, FOV=350x350x157.5mm³, matrix=256x254x63, TR/TE=3.4/1.7ms, turbo factor=50, scan duration=18s. For fat suppression a spectral selective adiabatic inversion pulse (SPAIR) with an inversion delay of 120ms was applied. Images were acquired twice first with the volume shim and then with IBS.

The quality of the fat saturation was graded visually: 4) images with homogenous fat suppression in both breasts; 3) remaining fat signal in one focal region; 2) remaining fat signal in both breasts; 1) failed fat saturation. Volume and IBS shim quality were statistically compared with a paired Student's t-Test.

Results:

Figure 1 shows example T1-weighted images with visual scoring of fat saturation quality. IBS shimming improved fat saturation in 40% of the cases compared to volume shim, in 55% no difference was observed and in 5% of the cases the fat saturation quality was slightly degraded. The mean score significantly improved from 3.36 with volume shim to 3.88 with IBS ($p=0.0003$). The distribution of the fat saturation quality is shown in figure 2. IBS shim quality did not change between the manual version A (3.90) and the automated version B (3.86).

Discussion and Conclusions:

Localized 2nd order shimming based on an acquired B_0 -map significantly improves the quality of fat saturation in breast imaging at 3T when compared to conventional linear volume shimming. In 88% of the patients homogenous bilateral fat suppression was observed with IBS, while the remaining 12% showed only one focal region with residual fat signal. Image based shimming in the breast was performed fully automated and without time penalty.

References:

1. Bedrosian I et al., Cancer 98, p.468, 2003; 2. Kuhl CK et al., Radiology 239, p.666, 2006; 3. Rakow-Penner R et al., J Magn Reson Imaging 23, p.87, 2006; 4. Schär M et al., Magn Reson Med 51, p799, 2004

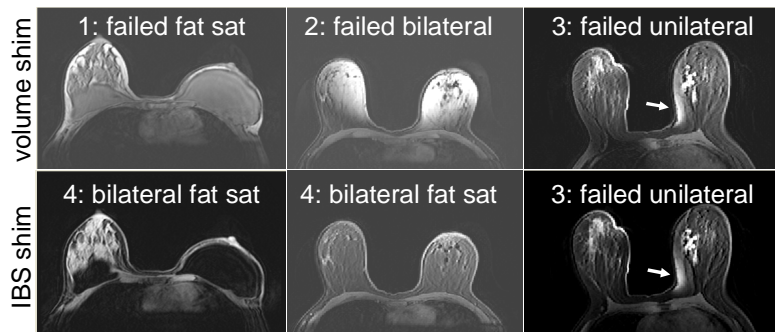


Figure 1: Example datasets and visual scoring of fat saturation quality. Data in top and bottom row were acquired with volume shim and IBS, respectively.

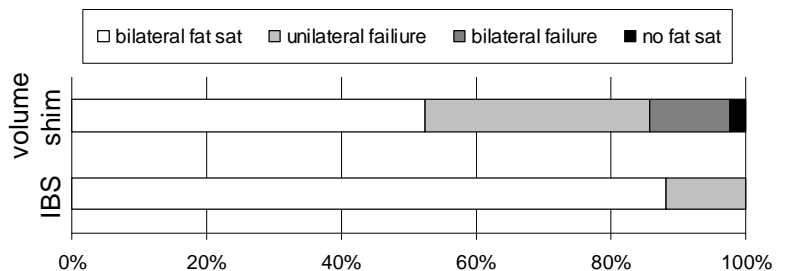


Figure 2: Distribution of fat sat quality in 42 patients with either linear volume shim or 2nd order IBS shim.