

# Diagnostic accuracy of high-resolution multi-shot diffusion-weighted MRI for the detection of breast cancer

W. B. Veldhuis<sup>1</sup>, C. Liu<sup>1</sup>, Y. Do<sup>1</sup>, M. E. Moseley<sup>1</sup>, and B. L. Daniel<sup>1</sup>

<sup>1</sup>Dept of Radiology / Lucas MRI Center, Stanford University, Palo Alto, California, United States

## Introduction

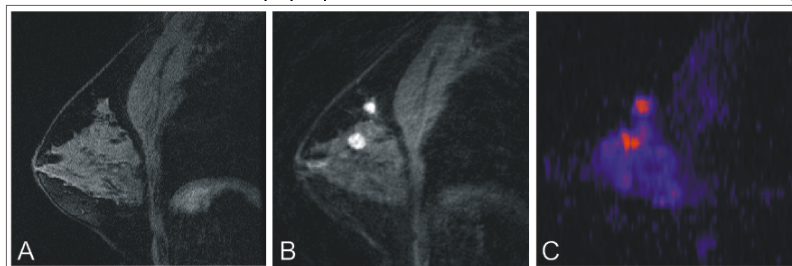
Diffusion-weighted imaging (DWI) may provide information - physically unrelated to microvascular changes detected by contrast-enhanced MRI - that can improve the specificity of MRI for breast cancer diagnosis. Attempts thus far to benefit from the information content that DWI may offer have been limited by the use of single-shot techniques, with inherent sensitivity to geometric distortions and limitations in detected lesion size<sup>[1,2]</sup>. The aim of this HIPAA-compliant, IRB-approved study was to compare the sensitivity and specificity of high-resolution DWI of the breast to 'conventional' dynamic-contrast enhanced MRI, and to pathology.

## Methods

**Patient population.** We performed a retrospective analysis of diffusion-weighted data sets acquired in 103 consecutive women (mean age 50.3 years, range: 15-81) undergoing 1.5T MRI for the evaluation of breast cancer. **MR imaging.** Free-breathing, axial, bilateral DW images were acquired with a 256x256 matrix, 20 spiral interleaves;  $b=75,450 \text{ s/mm}^2$ , 2 NEX for the highest  $b$ -value; spectral-spatial water-selective excitation; TR/TE=5000/45msec; slice-thickness/gap=5/0mm<sup>[3]</sup>. For dynamic contrast-enhanced (DCE-)MRI, a T1-weighted, 3D spiral sequence with spectral-spatial water excitation was used, which acquires simultaneous bilateral data sets at an 11 sec temporal and 0.78x0.78x4.4 mm spatial resolution. **DWI post-processing.** Functionally-thresholded (ftADC-) maps were derived from the original ADC maps and the  $b_{\max}$  DW-images, by inverting the  $0.55 \cdot 10^{-3} < t < 2.25 \cdot 10^{-3} \text{ mm}^2/\text{s}$  band of ADC values, while retaining the zero-mask, and subsequently creating maps from the product of this inverted value-band and the  $b_{\max}$  DW-images. **Data analysis.** Analysis of the DWI- and ftADC-images consisted of prospectively marking any high-signal intensity area as "DWI-suspicious" or "ftADC-suspicious" respectively. Analysis of the non-DW sequences was performed separately by one of four fellowship-trained radiologists according to the ACR Breast Imaging and Reporting Data System (BIRADS)-criteria. After the exams for all patients were processed, the available data including all pathology reports were compiled for further analysis.

## Results

7 patients were excluded before final analysis because DWI imaging was technically inadequate. Pathological confirmation was obtained for all but 1 of the lesions marked as 'suspicious' on ftADC. This 'lesion' was judged to be a normal lymph node on the basis of the non-DWI sequences and was stable over 2 years on 2 follow-up exams. It was thus scored as ftADC false-positive. Fig. 1 shows sagittally acquired T1W images and the corresponding sagittally reformatted ftADC-map of a 38-year-old woman with multifocal cancer. Table 1 compares the diagnostic accuracy of DCE-MRI to the accuracy of the blind-analysis of DWI or ftADC. The data shown is based on 65 pathology-proven lesions in 49 patients. As expected, the sensitivity of DCE-MRI was very high, with a lower specificity. The specificity of blind DWI- and especially of the blind ftADC-analysis, was much higher. While the increased specificity of ftADC analysis was coupled with a decrease in sensitivity compared to DCE-MRI, Table 1 shows the accuracy that can theoretically be reached when the ftADC-analysis is not done blindly, but in a clinical setting. I.e.: with knowledge of the patient history and, importantly, combined with conventional T1- and T2-weighted MRI; but not with contrast-enhanced MRI. This calculation is based on two assumptions: a) BIRADS-6 known cancers, often post radio- and/or chemotherapy, are scored as known cancers even if ftADC-dark; and b) ftADC-bright lesions that without diffusion would have been judged to be normal axillary lymph nodes, are scored as normal axillary lymph nodes. With the addition of this knowledge to the ftADC-analysis, the sensitivity increases to 95.7%.



**Fig 1.** Pre- (A) and post- (B) contrast T1W-images showing two pathology-proven invasive ductal cancers; C. ftADC-map derived from the DW-data set (acquired before contrast injection).

**Discussion** - The present data suggest that a contrast-free MRI-protocol, that includes DW imaging, may have a clinically acceptable diagnostic performance. This is relevant in light of recent issues with gadolinium-induced nephrogenic systemic fibrosis, and may also be relevant to discussions on breast cancer screening with MRI. Furthermore, it was shown that adding ftADC-mapping further improves specificity over adding DWI alone, without the need to define a rigid benign-malignant ADC-cutoff value. Lastly, we are aware that the conventional breast imaging protocol will include contrast-enhanced-sequences for some time to come. However, even with such a protocol, patients may still benefit from a diagnosis-modifying effect - in terms of up- or down-staging - of adding ftADC-maps to the analysis. For the current data set, retrospective addition of ftADC-mapping resulted in the correct downstaging of 22 of 65 pathology-verified lesions (data not shown). Large, multi-center validation will have to precede actual clinical implementation of this technique.

**Acknowledgments:** KWF - Dutch Cancer Society; NIH-5K99EB007182-02

**References:**<sup>[1]</sup>Rubesova E, *JMRI* 2006, 24(2):319-24; <sup>[2]</sup>Marini C, *Eur Rad* 2007, 17(10):2646-55; <sup>[3]</sup>Liu C, *MRM* 2004, 52(6):1388-96

**Table 1 - Diagnostic accuracy of hi-res DWI vs DCE-MRI for the detection of breast cancer (n=65 lesions)**

	DCE-MRI Birads 4-5	DCE-MRI Birads 3-5	DWI alone	ftADC alone	Combined
PPV	59.0%	50.0%	71.4%	85.0%	95.7%
NPV	100.0%	50.0%	91.9%	86.7%	97.6%
Sensitivity	100.0%	100%	87.0%	73.9%	95.7%
Specificity	61.9%	45.2%	81.0%	92.9%	97.6%

**Combined:** Accuracy based on combined analysis of the T1- and T2-weighted sequences + ftADC (no contrast-enhanced sequences); Improves on using DWI or ftADC alone because structures identifiable as normal lymph nodes on conventional MRI, are scored as normal lymph nodes regardless of their ftADC appearance; and because BIRADS-6 lesions (known cancers) are always 'suspicious', regardless of their ftADC appearance.