

Measuring blood movement in the placenta using IVIM at 1.5 T

A. M. Al-Radaideh¹, V. Kareem¹, C. Costigan², N. Jones³, T. Paus⁴, G. Bugg³, and P. A. Gowland¹

¹Sir Peter Mansfield Magnetic Resonance Centre, The University Of Nottingham, Nottingham, United Kingdom, ²Brain and Body Centre, The University Of Nottingham, Nottingham, United Kingdom, ³The University Of Nottingham, Nottingham, United Kingdom, ⁴Brain and Body Centre, The University of Nottingham, Nottingham, United Kingdom

Introduction: Placental blood flow is an important determinant of fetal outcome; poor perfusion is associated with intrauterine growth restriction (IUGR), pre-eclampsia and maternal diabetes. Diffusion Weighted Imaging (DWI) can be used to measure parameters related to placenta perfusion based on the intravoxel incoherent motion (IVIM) principle [1], which has high sensitivity in the placenta due to the large moving blood volume [2]. DTI data acquired with increasing b values show bi-exponential signal attenuation, modelled by

$$S = S_0 (f e^{-bD^*} + (1-f) e^{-bD}) \quad (1)$$

where S_0 is the equilibrium signal, D is the diffusion coefficient, D^* is the apparent diffusion coefficient and f is the moving blood volume (Fig 1). The relatively uniform magnetic susceptibility of the uterine contents makes placental DTI imaging using EPI relatively insensitive to artefacts. Furthermore, motion is less of a problem for the placenta than for the fetus. We have previously measured placental IVIM at 0.5 T [3]. This study aims to investigate the feasibility of using IVIM to measure placental blood movement at 1.5 T, providing increased sensitivity to flow but also potentially increased sensitivity to susceptibility artefacts. Also this study aims to investigate the use of histogram analysis of these data [4], based on the hypothesis that the homogeneous placental perfusion (where all the fetal villi are exposed to maternal blood) is more important for fetal growth than the mean placental perfusion which may be dominated by regions of high flow adjacent to spiral arteries.

Material and Methods:

Pregnant volunteers were recruited from Nottingham University Hospital and consented according to local ethics approval. Although most pregnant women were scanned once, some were scanned more than once at target gestational ages of 22 ± 2 , 28 ± 2 , 31 ± 2 or 36 ± 1 weeks. They were scanned using 1.5T Philips Achieva scanner with a SENSE Body receive coil and with specific absorption rate (SAR) $< 2W/kg$ [5]. A number of anatomical scans were performed for fetal-organ volumetry. The DTI sequence was a pulsed gradient spin echo sequence ($350 \times 350 \times 63 \text{ mm}^3$ resolution; $2.2 \times 2.76 \times 7 \text{ mm}^3$ FOV; TE=95ms; TR=3000ms; slices=5; 12 b-values [0, 1, 3, 15, 47, 80, 115, 206, 246, 346, 346, 468, 800 s/mm^2 ; total scan time per repeat = 1:51 min). This was repeated 5 times. To minimize scan time, respiratory gating was not used, but the women were asked to coordinate their breathing to the sound of the scanner. Data analysis was performed in Matlab. The analysis included drawing ROIs to cover the whole placenta, and then manually shifting these to account for any motion. Within the ROI the data were fitted to equation 1 for f , D , D^* and S_0 , on a pixel by pixel basis and overlay maps of these parameters were formed. A smaller ROI was then drawn within the main body of the placenta, avoiding the basal plate (as indicated on S_0 map). The average value of each parameter in this ROI was calculated. Finally, histograms were produced of the fitted parameter values within each ROI and the fraction of pixels with $0.01 < f < 0.05$ were calculated for each subject. The lower threshold was set because the fitting program placed badly fitted data points at $f=0$. The upper threshold was chosen to select approximately the 1st centile of voxels.

Results

Figure 1 shows maps of S_0 , f , D and D^* overlaid on T2* weighted EPI images from a single repeat. These clearly indicate increased values for all IVIM parameters in the uterine wall and basal plate (region of spiral arteries feeding the maternal blood volume of the placenta) and also indicate some lobular structure within the main body of the placenta. Figure 2 shows histograms of the values of the IVIM parameters within an ROI. Figure 3 shows the average value of f plotted against gestational age for all subjects. Figure 4 shows the fraction of the region of interest with $0.01 < f < 0.05$ plotted against gestational age for all subjects.

Discussion

This study has shown that DTI can be used to measure IVIM parameters related to placental blood movement at 1.5 T. Previous placental IVIM data acquired at 0.5 T only provided sufficient SNR to map f , but the functional structure observed in Figures 2 c and d suggest that at 1.5 T sufficient SNR is available to obtain useful information from D^* and D . It can be seen from the error bars that despite the motion problems in the placenta, intrasubject repeatability between 5 successive measurements was generally good. Variability between slices and between repeated visits at short intervals is now being investigated. There is insufficient data to make firm predictions about the variations with gestational age or between normal and abnormal pregnancies, but it is interesting to note that the compromised pregnancies generally had relatively small average values of f across the ROI, and increased fractions of the placenta showing low perfusion. The model shown in equation 1 is an approximation for the actual pattern of signal decay in this sequence. Intravoxel dephasing in this sequence depends on exact the pattern of the flow field in a voxel, and this data, and data acquired with different gradient waveforms could provide valuable input data for mathematical models of blood flow in the placenta. Future work will study variations in the different IVIM parameters in different regions of the placenta, with gestational age and between normal and compromised pregnancies.

1. Lebihan et al, J. Com. Ass. Tomo., 15, 1, 19-25, 1991.
2. Pekar et al, Magn. Res. Med., 23, 122-129, 1992.
3. Moore et al, Magn. Res. Med., 21, 7, 726-732, 2000.
4. Francis et al, Lancet, 351(9113), 1397-1399, 1998.
5. Gowland and de Wilde, Phys Med Biol, 53, L15-18, 2008.

Acknowledgements: The Hashemite University, Jordan for my studentship, University of Nottingham Brain and Body Centre for funding scanning.

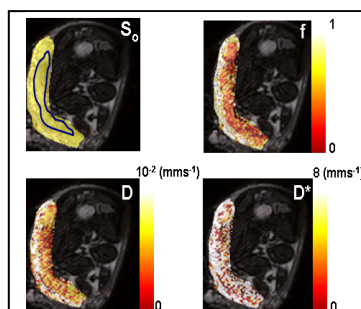


Figure (1) Parameter maps overlaid on EPI scans.

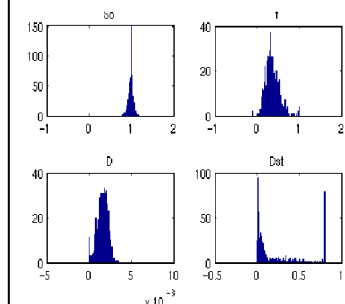


Figure (2) Shows a histograms of S_0 , f , D , and D^* values.

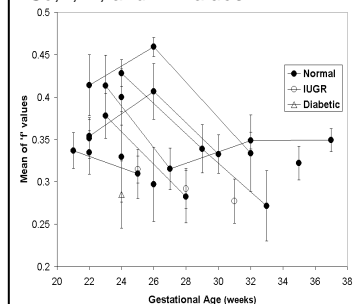


Figure (3) Mean values of f for different subjects as a function of gestational age. Points representing the same subject rescanned at different gestational ages are joined by straight lines. The error bars indicate the standard deviation between 5 repeats of the measurement on the same subject.

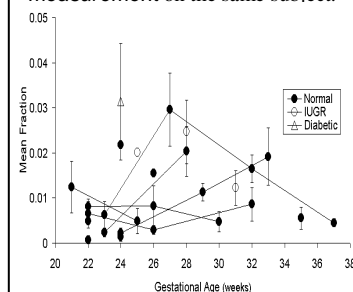


Figure (4) A fraction of the placenta with $0.01 < f < 0.05$ as a function of gestation age. (Other features as for figure (3)).